

Clinical Relevance of Sex and Age Related Variation in Corpus Callosum Morphology

By

Adrienne Ann Acar

Submitted in fulfilment of the requirements for the degree

Master of Science (Neuroanatomy)

Department of Anatomy
School of Medicine
Faculty of Health Sciences
University of Pretoria
South Africa

2016 – 2017

Supervised by

Mrs R Human-Baron, Department of Anatomy, University of Pretoria
Mrs G Venter, Department of Anatomy, Sefako Makgatho Health Sciences
University
Prof MC Bosman, Department of Anatomy, University of Pretoria

Acknowledgements

This study would not have been possible without the understanding and assistance of the following individuals:

- Dr Ilse Debeil and her team of radiologists from the Department of Radiology, Muelmed Mediclinic Hospital in Pretoria
- Professor Khan and Johannah from the Department of Radiology, Kalafong Hospital in Pretoria
- Brendon Billings from the Department of Anatomy, University of Witwatersrand

Thank you very much. Your assistance came at a time when I did not believe this Masters was possible. For that, I am forever grateful.

I would like to thank Sabashnee and Tiaan for assisting me at times when I couldn't be there myself. Your willingness to help me with anything at any time was truly appreciated.

Thank you to my friends and family who were there for me throughout everything. Your support helped me through the tough times, and allowed me to push through until the end.

To Rene, my supervisor and mentor. This project would not have come to life without you. I would like to thank you for your calm in times of stress, and your willingness to complete this project with me through correspondence. Your faith in my abilities has been incredible, and truly appreciated. Thank you.

I would like to acknowledge the financial support provided by the University of Pretoria Research Development Program.

Last but not least, I would like to acknowledge that hard work, persistence and dedication mean that anything is possible.

Abstract

Anatomical research of the morphology of the corpus callosum (CC) has provided a baseline for normal development of the CC. Although a large extent of variation amongst individuals has been reported, there are certain asymmetries that are consistently found in the size and shape of the CC on a midsagittal view of the brain. As the CC is the major commissural tract in the brain, it is acceptable to assume that structural variation in the CC may give clues towards the diagnosis of specific diseases. Studies relating alterations in the size and shape of the CC to the diagnosis of disorders have been done in individuals with schizophrenia, bipolar disorder (and depression. Thus, knowledge of CC anatomy in association with sex and age related changes can be helpful in providing a baseline for the diagnosis and progression of a specific disease. Morphological changes with regard to sex and age have been the topic of an extensive amount of research. However, there still remains considerable controversy as some studies report significant differences and others report none.

The aim of this study was to provide a detailed description of the anatomy and variations of the corpus callosum morphology in a South African population. A primary data set was compiled using a cadaveric population, and these results were compared to a secondary data set, using a healthy living population. Lastly, the results from both data sets were then compared with a third data set, comprising of a mental disorder population, and results gained from previous studies in order to determine possible diagnoses of certain mental disorders based on CC morphology.

In this study, there was no sexual dimorphism observed in the thickness of the genu, splenium and trunk in all three samples. In the cadaver sample there was no difference in the length of the CC. In the mental disorder sample there was no sexual dimorphism in the length of the CC and cerebrum. However, in the cadaver sample there was a significant difference in the length of the cerebrum between the sexes. In the healthy MRI scan there was a statistically significant difference observed in the length of the CC and the length of the cerebrum. It was found that there was no statistically significant difference in the thickness of the genu, trunk, and length of the

CC and length of the cerebrum with age in all three samples measured. There was a statistically significant difference observed in the thickness of the splenium in the healthy MRI scan sample in individuals over the age of 60 years of age. This difference was not observed in the cadaver or mental disorder sample. There were no statistically significant differences in the various CC parameters measured in the various mental disorders measured.

With the exception of two parameters, no differences in measurements were observed between the cadaver and healthy MRI sample. The two exceptions were the thickness of the trunk and the length of the cerebrum. Therefore, with the exception of the above mentioned cases, measurements between cadavers and living samples can be used interchangeably. Thus, the concerns about shrinkage in cadaver studies are negligible. However, when comparing the cadaver and healthy MRI scan sample with the mental disorder CT scan sample there was a statistically significant difference observed in every CC parameter measured. Thus, there is a rather noticeable difference in the anatomical structure of the CC in individuals suffering from mental disorders. Data on normal CC morphology is under represented in the South African population. Observations of variations from normal CC morphology can be used as an indicator for the possibility of a mental disorder.

Table of Contents

Acknowledgements	ii
Abstract	iii
List of Figures	vii
List of Tables	Error! Bookmark not defined.
List of Abbreviations	xi
1. Introduction	1
1.1 The importance of clinical anatomy and cadaver research	1
1.2 Brief history of the corpus callosum	3
1.3 Anatomy of the corpus callosum	4
1.4 Function of the corpus callosum.....	7
1.5 Techniques for partitioning the corpus callosum	9
1.6 Variability in the anatomy of the corpus callosum	12
1.6.1 Variability between females and males in the corpus callosum	12
1.6.2 Variability with age in the corpus callosum	16
1.6.3 Mental disorders associated with alterations in the corpus callosum....	19
1.7 Possible reasons for contradictions in the literature	25
2 Aims and Objectives	27
2.1 Aims	27
2.2 Research Objectives	27
3 Materials and Methods	28
3.1 Ethical Clearance	28
3.2 Study design	28
3.3 Procedures and criteria for selection.....	30
3.3.1 Cadaver study	30
3.3.2 Imaging study – healthy.....	34
3.3.3. Imaging study – mental disorders.....	37
3.4. Statistical analyses.....	40
4. Results	42
4.1 Cadaver study	42
4.2 Imaging study – healthy	53

4.3	Imaging study – mental disorders	62
4.4	Comparison between the three samples	74
5	Discussion.....	82
5.1	Sex differences in total midsagittal callosal length and length of the brain..	83
5.2	Sex differences in subregions of the CC	85
5.2.1	Thickness of the genu (TG).....	85
5.2.2	Thickness of the splenium (TS)	86
5.2.3	Thickness of the trunk (TT).....	87
5.3	Age differences in total midsagittal callosal length and length of the brain .	89
5.3.1	Length of the CC (LC).....	89
5.3.2	Length of the cerebrum (LB).....	90
5.3.3	Thickness of the genu (TG).....	91
5.3.4	Thickness of the splenium (TS).....	92
5.3.5	Thickness of the trunk (TT).....	93
5.4	Psychiatric differences in CC subregions	95
5.5	Comparison between the three sample sets	97
6	Conclusion	101
6.1	Limitations	102
6.2	Future Research	103
7	References.....	105

List of Figures

Figure 1. Midsagittal view showing different sections of the corpus callosum	5
Figure 2: Midsagittal section of the CC showing the 7 subregions	10
Figure 3: Midsagittal section of the CC showing the radial subregions	11
Figure 4: Midsagittal section of the CC showing the curved line subregions.....	11
Figure 5. Cadaver brain demonstrating the Witelson method of partitioning	29
Figure 6. Standardized measurement of the genu	32
Figure 7. Standardized measurement of the splenium	32
Figure 8. Standardized measurement of the corpus or trunk	33
Figure 9. Standardized measurement of the CC	33
Figure 10. Standardized measurement of the cerebrum	34
Figure 11. Standardized measurement of the genu	35
Figure 12. Standardized measurement of the splenium	35
Figure 13. Standardized measurement of the corpus or trunk	36
Figure 14. Standardized measurement of the CC	36
Figure 15. Standardized measurement of the cerebrum	37
Figure 16. Standardized measurement of the genu	38
Figure 17. Standardized measurement of the splenium	38
Figure 18. Standardized measurement of the corpus	39
Figure 19. Standardized measurement of the CC	39
Figure 20. Standardized measurement of the cerebrum	40
Figure 21. Sex distribution of cadaver sample	42
Figure 22. Age distribution of female cadaver sample.....	43
Figure 23. Age distribution of male cadaver sample	43
Figure 24. Mean comparison of CC parameters between the sexes.....	45
Figure 25. Sex distribution of the MRI scan sample	53
Figure 26. Age distribution of female MRI scan sample	53
Figure 27. Age distribution of male MRI scan sample	54
Figure 28. Mean comparison of CC parameters between the sexes in the MRI scan sample.....	55
Figure 29. Sex distribution of mental disorder CT scan sample	62
Figure 30. Age distribution of female mental disorder CT scan sample	63

Figure 31. Age distribution of male mental disorder CT scan sample	63
Figure 32. Mental disorder distribution for CT scan sample	64
Figure 33. Mean comparison of CC parameters between the sexes in mental disorder CT scan sample	66

List of Tables

Table 1: Sexual dimorphism in the literature	15
Table 2: Age related variations in the literature	18
Table 3: Variations of schizophrenia in the literature.....	22
Table 4. Variation of bipolar disorder in the literature	23
Table 5. Variations of depression in the literature	24
Table 6. Variations of Alzheimer's disease in the literature	24
Table 7: Measurements that were taken of the CC	30
Table 8. Descriptive statistics of female cadaver sample	44
Table 9. Descriptive statistics of male cadaver sample	44
Table 10. Descriptive statistics of various age groups for female cadaver sample ..	46
Table 11. Descriptive statistics of various age groups for male cadaver sample	46
Table 12. Mean comparison between the sexes of the cadaver sample	48
Table 13. Mean comparison amongst various age groups.....	49
Table 14. Scheffe's test amongst various age groups.....	50
Table 15. Pearson's correlation of the cadaver sample.....	51
Table 16. Spearman's correlation of the cadaver sample	52
Table 17. Table showing frequency of isthmus and bulbous splenium	52
Table 18. Descriptive statistics of female MRI scans sample.....	54
Table 19. Descriptive statistics of male MRI scan sample.....	55
Table 20. Descriptive statistics of various age groups for female MRI scan sample	56
Table 21. Descriptive statistics of various age groups for male MRI scan sample ...	57
Table 22. Mean comparisons between sexes of the MRI scan sample.....	58
Table 23. Mean comparisons amongst various age groups of the MRI scan sample	59
Table 24. Pearson's correlation of the MRI scan sample	60
Table 25. Spearman's correlation of the MRI scan sample	60
Table 26. Table showing frequency of isthmus and bulbous splenium	61
Table 27. Descriptive statistics of female CT scan sample	65
Table 28. Descriptive statistics of male CT scan sample	66
Table 29. Descriptive statistics of various age groups for female CT scan sample..	67
Table 30. Descriptive statistics of various age groups for male CT scan sample.....	68

Table 31. Descriptive statistics for the various mental disorders	69
Table 32. Mean comparison between the sexes for CT scan sample	70
Table 33. Mean comparison amongst various age groups for the CT scan sample	71
Table 34. Mean comparison of various mental disorders for CT scan sample	72
Table 35. Pearson's correlation of CT scan sample	73
Table 36. Spearman's correlation of CT scan sample	73
Table 37. Table showing frequency of isthmus and bulbous splenium	74
Table 38. Descriptive statistics of the three sample sets	75
Table 39. Mean comparison between the sample sets	78
Table 40. Scheffe's test between the sample sets	79
Table 41. Scheffe's test between the age groups	81
Table 42. Table showing length of cerebrum (LB)	83
Table 43. Table showing length of CC (LC)	84
Table 44. Table showing thickness of genu (TG)	86
Table 45. Table showing thickness of splenium (TS)	87
Table 46. Table showing thickness of trunk (TT)	88
Table 47. Table showing length of CC (LC)	90
Table 48. Table showing length of cerebrum (LB)	91
Table 49. Table showing thickness of genu (TG)	92
Table 50. Table showing thickness of splenium (TS)	93
Table 51. Table showing thickness of trunk (TT)	94
Table 52. Table showing comparisons between mental disorders	96
Table 53. Table showing comparisons between sample sets	97

List of Abbreviations

Analysis of Variance	(ANOVA)
Computerized Tomography	(CT)
Corpus callosum	(CC)
DF	
Diagnostic and Statistical Manual of Mental Disorders, 5 th Edition	(DSM – 5)
Digital Imaging and Communications in Medicine	(DICOM)
F-ratio	(F)
International Statistical Classification of Diseases and Related Health Problems, 10 th Revision	(ICD 10)
Length of the cerebrum	(LB)
Length of the corpus callosum	(LC)
Magnetic Resonance Imaging	(MRI)
Multivariate Analysis of Variance	(MANOVA)
Standard Deviation	(SD)
Thickness of the genu	(TG)
Thickness of the splenium	(TS)
Thickness of the corpus or trunk	(TT)
t-distribution	(t)

1. Introduction

1.1 The importance of clinical anatomy and cadaver research

Sound knowledge of the underlying anatomy is fundamental for the accurate definition and successful treatment of a medical concern experienced by a patient (Older, 2004). There is a lot of emphasis placed on clinical anatomy in the teaching of medicine and thus, it can be said that clinical anatomy is an important stepping stone for all surgical procedures (Miles, 2005). Advances in current neurosurgical techniques have been developed and mastered through cadaver dissection (Suri *et al.*, 2014). This has created the belief that any part of the brain, which as previously considered “no man’s land”, can be operated on (Suri *et al.*, 2014).

The use of cadavers to teach clinical anatomy has been long-standing in medical education. However, due to ethical considerations and public opinion of cadaver programmes, the availability of human material has been on the decline for higher education institutions (Gunderman and Wislon, 2005). Recent research has suggested that cadaver dissections are fundamental in providing hands-on experience in the exploration of human tissue, as well as a rite of passage into the medical field (Gunderman and Wislon, 2005). When asked, students agreed that cadaver dissection deepened their understanding and provided a three-dimensional model of anatomical structures, as well as helping them recall what they have learnt during the semester (Azer and Eizenberg, 2007).

Although imaging diagnostic techniques such as ultrasound and magnetic resonance imaging become more accurate daily, the use of cadaver studies remains important when clarifying anatomical-morphological features (Reinoso-Barbero *et al.*, 2014). A potential limitation on the use of data collected from a cadaveric study is that the embalming technique could cause anatomical shrinkage and distortion, which could create a bias in the results. For this reason, a living population component is often added to the cadaveric study in order to compare the results gained and see if it is an accurate representation of a living population and to translate the research into a clinical environment (Schoeman, 2016).

Anatomical research on the morphology of the corpus callosum (CC) has provided a baseline for normal development of the CC. It has been noted that there are certain alterations in CC morphology in individuals with psychiatric and developmental disorders when compared to healthy individuals (Bloom and Hynd, 2005). Studies relating alterations in the size and shape of the CC to the diagnosis of disorders have been done in individuals with schizophrenia (Chua *et al.*, 2000, Collison *et al.*, 2014, Ellison-Wright *et al.*, 2014), bipolar disorder (Brambilla *et al.*, 2003, Matsuo *et al.*, 2009, Li *et al.*, 2014) and depression (Wu *et al.*, 1993, Lyoo *et al.*, 2002, Bae *et al.*, 2006).

The CC consists of compact white fibres and is the most prominent forebrain structure with four easily identifiable parts; the rostrum, genu, corpus (trunk) and the splenium (Raybaud, 2010). A central thinning, the isthmus is present in a small percentage of individuals, and is considered the fifth component when present. The CC extends from the anterior commissure in the frontal lobe to the parietal lobe (Raybaud, 2010). As recently as the mid-20th century it was thought that the only function of the CC was to prevent the two cerebral hemispheres from collapsing on one another (Mooshigian, 2008). However, current research has shown that the CC plays an essential role in bilateral information integration between the cortical and subcortical regions in both the left and right hemispheres, as well as body coordination (Sungathy *et al.*, 2003, Raybaud, 2010).

Although a large extent of variation amongst individuals has been reported, there are certain asymmetries that are consistently found in the size and shape of the CC on a midsagittal view of the brain (Bloom and Hynd, 2005, Westerhausen *et al.*, 2006, Fenlon *et al.*, 2015). As the CC is the major commissural tract in the brain, it is acceptable to assume that structural variation in the CC may give clues towards the diagnosis of specific diseases.

An extensive review of current literature shows that there is considerable controversy with regard to variations with sex and age in the morphology of the CC. Most of the studies on CC morphology have been conducted on European (Sungathy *et al.*, 2003, Tuncer *et al.*, 2005, Ozdemir *et al.*, 2007, Gupta *et al.*, 2008) and/or American populations (Salat *et al.*, 1997, Sullivan *et al.*, 2001, Dubb *et al.*, 2003, Lebel *et al.*,

2010, Luders *et al.*, 2014, Prendegrast *et al.*, 2015). There has been one study conducted on a South African population, but this did not include cadavers (Constant and Ruther, 1996). Therefore, there has been no comparison between cadaver and living samples in a South African population as well as no comparison between a healthy sample and mental disorder sample. Thus, there is a need for an anatomical study that focuses on the variations, if any, with sex and age seen in the morphology of the CC in a cadaveric and living sample – both normal and diseased – in a South African population.

1.2 Brief history of the corpus callosum

Galen was the first to describe the CC in the second century and this was gained from his knowledge through surgery as a physician, as well as through animal dissection (Clarke and O'Malley, 1996). However, his description was vague and lacked details as he based most of his observations on animal anatomy. It was the only description of the CC until the 16th century when Vesalius expanded the details in order to provide a better anatomical map of the structure (Broadfield, 2001).

Once a description of the anatomy of the CC was available, it allowed for research into the functioning of this structure. At the time, there was a debate about which part of the brain was the “seat of the soul”; the two main views were the pineal gland versus the corpus callosum (Broadfield, 2001). A physician named Giovanni Maria Lancisi in 1741 speculated that the CC was indeed the “seat of the soul” because in his experiments he observed that injuries to the pineal gland did not result in death, while injuries to the CC did (Broadfield, 2001).

In the 1920s, Ivan Pavlov observed that dogs that were conditioned to salivate when presented with a stimulus at a specific location on one side of the body, responded in a similar fashion when presented with a stimulus on the other side of the body (Pavlov and Anrep, 1927). This led to an experiment in which the CC was severed in dogs and they were conditioned using the same techniques described above (Broadfield, 2001). It was found that the dogs displayed no evidence of bilateral information transfer after their CC's had been severed, thereby demonstrating the role of the CC in interhemispheric transfer of information (Broadfield, 2001).

Subsequent to this discovery, researchers conducted more studies on animals involving the severing of the CC in order to study the motor and memory deficits that arose (Broadfield, 2001).

This has led to more research into the functioning of the CC in normal development, as well as in studies that focus on abnormal development and how it affects normal functioning of the CC.

1.3 Anatomy of the corpus callosum

The CC is the most prominent forebrain structure which consists of compact white matter composed of commissural nerve fibres which connect the cortical and subcortical regions of the right and left hemispheres (Georgy *et al.*, 1992, Gupta *et al.*, 2008). The CC is unique to placental mammals only, and it has been suggested that the purpose of this evolutionary development was to facilitate long-distance integration within larger brains (Paul, 2010).

The first callosal fibres are found in human embryos at 10 – 11 weeks of gestation, after which these fibres start to form a rudimentary callosal plate by 12 -13 weeks (Bloom and Hynd, 2005). The correct formation of precise connections between the cortical and subcortical areas of the brain is essential for integration of lateralized sensory input and coordination of higher-level cognitive, emotional and social processing (Fenlon and Richards, 2015). This is carried out by a complex process known as midline crossing; which involves new-born callosal neurons that undergo a complex interaction with axon-guidance cues that allow the callosal axons to extend towards, across and then away from the midline (Fenlon and Richards, 2015). This results in the topographical organization of the CC, which allows for the fibres to connect the contralateral regions in which the cells bodies are located (Paul, 2010, Fenlon and Richards, 2015). In normal development of the CC, it is shown that as the frontal lobes expand, the anterior border of the CC moves progressively forward (Kier and Truwit, 1996). While the splenium, isthmus and body of the CC are shown to have on-going development well into adulthood and this is seen to be consistent with the continued maturation of higher association areas (Giedd *et al.*, 1996).

The CC is attached rostrally to the lamina terminalis (from which it originates) and then extends caudally, superior to the lateral ventricle, to end approximately 7 cm from the occipital pole (Bosman, 2008). The CC is located in the longitudinal fissure and the superior surface is covered by a thin layer of grey matter, the induseum griseum, with the medial and lateral longitudinal stria attached to it (Bosman, 2008). The inferior border of the CC is related to the anterior horn of the lateral ventricle and the columns of the fornix (Bosman, 2008) and forms the anterior and superior border of the septum pellucidum (Raybaud, 2010).

The CC is divided into four easily identifiable parts in the midsagittal plane from anterior to posterior; namely, the rostrum (beak), genu (bent knee), corpus (trunk) and the splenium (bandage), which are shown in Figure 1. A central thinning, the isthmus, is seen at the junction of the corpus and the splenium and is found in approximately 25% of individuals (Raybaud, 2010).

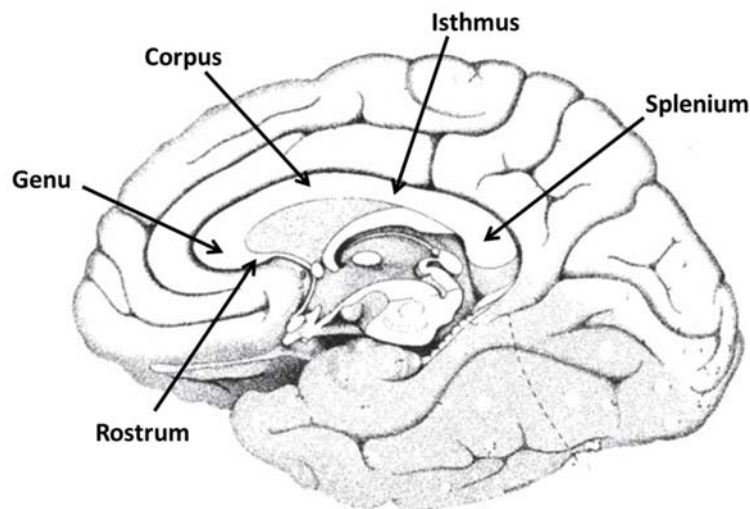


Figure 1. Midsagittal view showing different sections of the corpus callosum

Sectioning of the CC into its various subregions is commonly described using the geometrical classification scheme developed by Witelson in 1989. The rostrum extends anteriorly from the anterior commissure to the postero-inferior aspect of the genu and connects the orbital surfaces of the frontal lobe (Raybaud, 2010). The genu is the thickened anterior part of the CC and derives its name from the abrupt change in orientation of the fibres between the rostrum and the corpus (Raybaud, 2010). It has the thickest density of thin neural fibres arising in the anterior frontal

lobe, containing fibres of the ventro-medial prefrontal cortex in the ventral aspect of the genu and the fibres of the dorso-lateral prefrontal cortex in the dorsal aspect of the genu (Paul, 2010, Raybaud, 2010). Collectively these fibres are known as the forceps minor, and form the anterior limit of the septum pellucidum in the midsagittal plane. The corpus is the horizontal portion that extends from the posterior-most point of the genu to the point where the columns of the fornix touch the CC (Raybaud, 2010). The fibres which run through the corpus consist mainly of those from the precentral cortex and cingulate gyrus. The corpus can be further subdivided into the anterior midbody and the posterior midbody according to Witelson (1989). The anterior midbody contains larger and less dense fibres and connects the premotor and supplementary motor areas; while the posterior midbody connects the primary motor areas via large, highly myelinated, fast conducting fibres (Paul, 2010). They also form the roof of the lateral ventricles and the superior border of the septum pellucidum (Raybaud, 2010).

The isthmus, although seen in only a small percentage of individuals, is a crucial segment. The isthmus contains fibres from the pre- and postcentral gyri as well as those from the primary auditory area (Raybaud, 2010). The splenium is the thickest portion of the CC (Raybaud, 2010). The fibres of the splenium can be further divided into three parts; the superior group which contains fibres for the posterior parietal cortex, the posterior group which contains fibres for the medial occipital cortex, and finally the inferior group that contain fibres for the medial temporal cortex (Raybaud, 2010). Collectively, these fibres comprise the forceps major which contributes to the tapetum, along with the corpus (Raybaud, 2010). The forceps major connects the occipital lobes, while the tapetum connects the temporal lobes (Bosman, 2008). The shape of the splenium is recorded as bulbous when the widening is sudden and tubular when the widening is gradual (Sungathy *et al.*, 2003).

The lateral ventricles constitute a part of the cerebral ventricular system that is responsible for the transport of cerebrospinal fluid (CSF). Certain subregions of the CC form part of the borders of the lateral ventricle (Young, 2006). The anterior horn of the lateral ventricle is bordered below by the rostrum, anteriorly by the genu and superiorly by the trunk of CC (Young, 2006). The central part of the lateral ventricle lies inferior to the trunk of the CC. The posterior horn is bordered laterally by the

tapetum (Young, 2006). There is an observed increase in the ventricular volume during normal ageing of individuals and the close relation of the lateral ventricle with the CC, makes it reasonable to assume that the CC may be vulnerable to pressure by ventricular enlargement (Hyun-Kwon *et al.*, 2014).

1.4 Function of the corpus callosum

The fundamental function of the CC is to provide interhemispheric transfer between the homologous cortical and subcortical areas; however, there is a debate on exactly how that communication is achieved. The two main schools of thought are the theory of inhibition, in which the CC allows for one hemisphere to inhibit the function of the other, versus the theory of excitation, in which one hemisphere excites the activity of the other hemisphere (Bloom and Hynd, 2005). The CC is composed of two main fibre types, large diameter fibres that facilitate sensory and motor coordination and small diameter fibres that connect association areas (Bloom and Hynd, 2005). The location of these fibres is described above, and these fibres allow for specific information to be transferred in specific subregions of the CC.

When discussing the function of the CC, it is important to mention the field of research into asymmetry. This focuses on the lateralization of functionality and postulates that the different hemispheres are not identical when it comes to anatomy and function, which then leads to asymmetries in information processing (Bloom and Hynd, 2005). Evidence for lateralization of function can be found as early as the first hominids due to blows found on the left side of the prey's body, suggesting that the attacker was right handed, which is now defined as handedness (Bloom and Hynd, 2005). In modern day humans, evidence for asymmetries is also found. Most notably, in Broca's motor area for speech which is dominant and larger in the left hemisphere of the brain in right handed individuals. This functional asymmetry validates the theory that the left hemisphere is dominant for language, while the right hemisphere is dominant for emotional functions (Bloom and Hynd, 2005). This is further supported by experiments involving dichotic listening tasks in which subjects are exposed to two competing auditory stimuli to both ears simultaneously, and then asked to repeat what they heard. Subjects, who have left hemisphere dominance

with regard to language, reported the information presented to the right ear (Bloom and Hynd, 2005).

This obvious dominance of one hemisphere for a specific function gave rise to the theory of inhibition, in which it is believed that the CC facilitates a pathway for one hemisphere to inhibit another hemisphere in order to give preference to a specific function (Bloom and Hynd, 2005). This domination effect is achieved at the neural level, in which an increase in the firing rate of one neuron causes a decrease in the firing rate of the neuron that it synapses upon (Bloom and Hynd, 2005). The theory of inhibition was outlined in 1984 by Cook in which he demonstrated that, when a cortical area is inhibited by the homologous area in the opposite hemisphere, the immediately surrounding area becomes more active (Cook, 1984). Thus, a mirror-image pattern of activation and inhibition is seen in the two hemispheres (Cook, 1984). The theory has since been modified and now states that the two hemispheres are locked in a mutually inhibitory relationship and that the CC acts as a barrier to prevent information cross talk for specific functions in which one hemisphere is dominant (Bloom and Hynd, 2005).

There is some evidence to support the theory of inhibition, such as the dichotic listening tests as described previously. In an experiment conducted by Banich and Belger in 1990, it was demonstrated that when presented with tasks of varying difficulty, for the more complex tasks, individual performance was heightened by distributing the information processing in the same hemisphere (Banich and Belger, 1990). Thus, suggesting that the CC is involved in inhibiting bilateral information integration in order to enhance intrahemispheric processing (Bloom and Hynd, 2005).

The contradictory theory is the one of excitation in which the CC is believed to enforce bilateral information integration and processing between the two hemispheres, and thus, activates the unstimulated hemisphere (Bloom and Hynd, 2005). This excitation effect is also achieved at the neural level, in which an increase in the firing rate of one neuron also increases the firing rate of the neuron on which it synapses (Bloom and Hynd, 2005). This theory postulates that the integration between the two hemispheres increases the amount of cortex that is dedicated to

performing a specific task, thus improving the performance especially if it is a more complex task (Bloom and Hynd, 2005).

Some evidence to support the theory of excitation is seen in callosotomies. These are surgical procedures that sever the CC connection and are performed on patients with intractable epilepsy. It is believed that the CC serves as a channel in which seizures in the one hemisphere are then transferred and promoted in the other hemisphere (Bloom and Hynd, 2005). In split brain studies, patients display evidence of disconnection syndrome after callosotomies. These patients are unable to compare sensory information presented to the contralateral hemisphere. For instance being able to feel objects in the opposite hand, hear stimuli presented to the opposite ear and smell odours presented to the opposite nostril (Bloom and Hynd, 2005). This demonstrates that the CC is essential to transfer information to the contralateral hemisphere. This supports the theory of excitation as information is being transferred rather than suppressed.

Thus, evidence that supports both the theory of inhibition and excitation are found in the literature. The CC can be thought of as a collection of pathways that can act independently of one another, rather than being considered as a unitary body with a singular function. It can be suggested that there is not just one method of bilateral information transfer and processing, but several varieties that occur depending on the complexity of the task at hand, and that anatomical asymmetry reflects the dominance of the specific hemisphere for the specific task (Bloom and Hynd, 2005).

1.5 Techniques for partitioning the corpus callosum

There are many techniques that have been developed to segment the CC in order to make it easier to measure, and to ensure repeatability of those measurements. It has been suggested that the use of these different methods, along with their different orientations, could be a possible explanation for the conflicting results when measuring the CC (Constant and Ruther, 1996).

The first technique used for partitioning the CC is the straight line method developed by Witelson in 1989. This technique makes use of a straight line that is drawn from

the most rostral to the most caudal point of the CC (Witelson, 1989). The CC is then divided into halves, thirds and the posterior one fifth. This divides the CC into seven subregions; namely, the rostrum, the genu, the rostral body, the anterior midbody, the posterior midbody, the isthmus and the splenium of the CC (Witelson, 1989). These divisions are shown in Figure 2 below. Witelson (1989) divided the CC into these seven subregions based on the different fibre orientations in order to accurately partition each region; however, this technique is dependent on the size and shape of the genu and splenium which could give inconclusive results (Constant and Ruther, 1996, Tuncer *et al.*, 2005). Despite this, the straight line method is the most popular technique to partition the CC, and the method that will be used in this study.

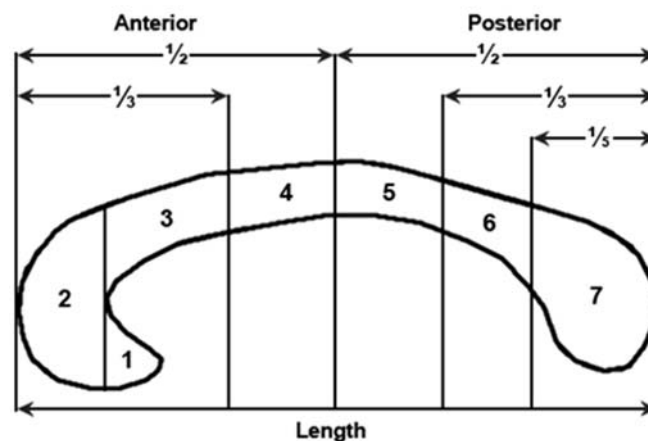


Figure 2: Midsagittal section of the CC showing the 7 subregions (Witelson. 1989)

The next technique is the radial partitioning method. This technique also makes use of a straight line that connects the most anterior point of the CC to the most posterior point (Broadfield, 2001). The midpoint of the line is determined, and the CC is divided into six subregions by projecting a radial divider that rotates every 30° from 0° through 180° (Broadfield, 2001, Ryberg *et al.*, 2006). With this technique, the genu and rostrum are considered together and both make up the most anterior division of the CC. Just posterior to the genu and rostrum is the rostral body. The midbody is divided into an anterior and posterior region, with the anterior midbody lying posterior to the rostral body. The isthmus is found posterior to the posterior midbody and anteriorly to the splenium, which is the most posterior region of the CC. The partitions of the CC using this method are shown in Figure 3 below, with an added

demarcation of the rostrum to demonstrate its position. The advantage of this technique is that it accurately divides the CC into various subregions, however, it relies heavily on the shape of the CC and this could indicate some form of bias (Ryberg *et al.*, 2006).

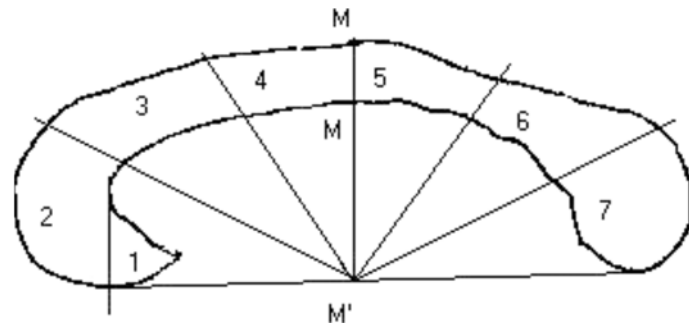


Figure 3: Midsagittal section of the CC showing the radial subregions (Ryberg *et al.*, 2006)

The final technique that will be discussed is the curved line method. This technique measures the length of the curved line which bisects the ventral and dorsal halves of the CC from the rostrum to the splenium (Allen *et al.*, 1991). An accurate line is obtained by drawing adjacent lines at 2 mm intervals between the dorsal and ventral surfaces of the CC, then determining the midpoint of these lines and connecting them to obtain the curved line (Allen *et al.*, 1991). The length of the CC can then be measured and divided into five sub regions. The divisions are shown in Figure 4 below. The advantage of this technique is that it is not dependent on the shape of the CC; however, if some parts of the CC are hard to define it can be difficult to accurately draw the line (Allen *et al.*, 1991). This method makes use of the splenial width (SW) and minimum body width (BW).

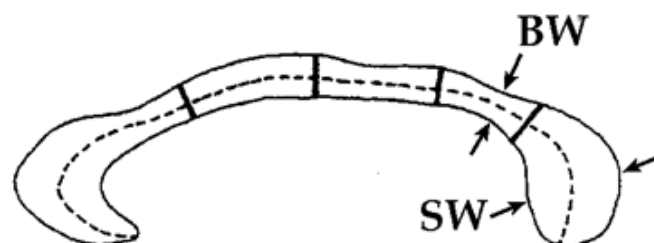


Figure 4: Midsagittal section of the CC showing the curved line subregions (Allen *et al.*, 1991)

1.6 Variability in the anatomy of the corpus callosum

Alterations in the morphology of the CC can give clues towards the processes of specific diseases. Thus, knowledge of CC anatomy in association with sex and age related changes can be helpful in providing a baseline for the diagnosis and progression of a specific disease (Gupta *et al.*, 2008). Morphological changes with regard to sex and age have been the topic of an extensive amount of research. However, there still remains considerable controversy as some studies report significant differences and others report none.

MR imaging, CT scans and cadaver specimens have been used for recording parameters in order to specify the shape and size of the CC (Bloom and Hynd, 2005, Gupta *et al.*, 2008, Mooshagian, 2008). In recent years, many of the studies on CC morphology have been conducted using MR imaging or CT scans – the advantage being that an intact living brain can be studied (Gupta *et al.*, 2008, Mooshagian, 2008). The areas that have been most often studied are the length of the CC, the maximum widths of the splenium, genu and rostrum, maximum and minimum widths of the corpus of the CC, distance between the genu and fornix, length of the brain anterior to posterior, and total callosal area (Clark *et al.*, 1994, Dubb *et al.*, 2003, Sungathy *et al.*, 2003, Westerhausen *et al.*, 2011, Prendergrast *et al.*, 2015).

1.6.1 *Variability between females and males in the corpus callosum*

There have been contradictory reports on sexual differences between males and females. A possible explanation is that the relationship between the CC and brain size is not always linear and can vary amid the sexes (Sullivan *et al.*, 2001). Thus, brain size must be accounted for in sex comparisons as it is generally agreed that men have larger bodies and brains than women (Sullivan *et al.*, 2001).

There are observable sexual differences in the human central nervous system that have influence over the sexual reproduction system, for example in the preoptic-anterior hypothalamic area responsible for gonadotropin release and in Onuf's nucleus in the spinal cord that contracts the perineal muscles (Constant and Ruther, 1996). Slight differences in cognitive tasks that have shown that females perform

better in verbal tasks, while males perform better in spatial and mathematical tasks, has led to research being conducted on the possibility of sexual differences in neuroanatomical structures that are not directly involved in sexual reproduction (Constant and Ruther, 1996).

Such common findings in the literature are represented in Table 1 below. These findings indicate that females generally have a larger splenium than males. In a study by Dubb *et al.*, (2003), 189 adult MRI brain scans were measured and it was found that there was a statistically significant larger width of the splenium in females ($p < 0.001$). This could be an indication as to why females perform better in language related tasks, as the splenium is involved in interhemispheric language transfer processing (Salat *et al.*, 1997, Dubb *et al.*, 2003). It has been observed that males have a larger genu than females, and this could be an indication as to why males perform better in spatial and motor tasks (Dubb *et al.*, 2003). In the same study of Dubb *et al.*, (2003), it was found that there was also a statistically significant larger width of the genu in males ($p < 0.001$) These results were supported by Prendegragst *et al.*, (2015) in which 305 MRI brain scans were analysed. Males are said to have a longer CC than females (Sungathy *et al.*, 2003, Gupta *et al.*, 2008, Sullivan *et al.*, 2001). Sungathy *et al.*, (2003) studied 100 normal MRI adult brain scans where it was found that the mean length of the CC was longer in males (72.6 ± 5.2 mm) than in females (70.6 ± 4.0 mm). These results are supported by Gupta *et al.*, (2008) in which the authors studied 44 formalin-preserved cadaver brains and 30 MRI adult brain scans. It was found that there was longer mean CC length in males (75.70 ± 6.20 mm) than in females (71.0 ± 4.10 mm). However, in a study conducted by Salat *et al.*, (1997) a longer CC was found in females. It was suggested that this was due to a larger splenium in females (Salat *et al.*, 1997).

There have several been studies (Bishop and Wahlstein, 1997, Ozdemir *et al.*, 2007, Luders *et al.*, 2014), that have not found sexual dimorphism in the CC morphology and these studies are represented in Table 1 below. A review conducted by Bishop and Wahlsten (1997) determined that there was no sexual dimorphic difference in the CC whether or not adjustments were made for whole brain or cortex size. Luders *et al.*, (2014) found that the CC was thicker in males than in females, and attributed it

to cerebral sex differences. In other words, the larger the sex discrepancy in brain size, the more pronounced the sex difference in CC length (Luders *et al.*, 2014).

Table 1: Sexual dimorphism in the literature

Study	Subjects	Population	Results
Evidence for sexual dimorphism in CC morphology			
Constant and Ruther (1996)	104 MRI adult brain scans	South Africa	Rostral body larger in females ($p=0.034$). No other dimorphism found
Salat <i>et al.</i> , (1997)	76 Elderly MRI adult brain scans	United States of America	Length of CC longer in females ($p=0.094$) Larger splenium in females
Sullivan <i>et al.</i> , (2001)	92 MRI adult brain scans	United States of America	Length of CC longer in males
Dubb <i>et al.</i> , (2003)	189 Adult MRI brain scans	United States of America	Larger splenium in females ($p<0.001$) Larger genu in males ($p<0.001$)
Sungathy <i>et al.</i> , (2003)	100 MRI adult brain scans	India	Length of CC longer in males (72.6 ± 5.2 mm) than in females (70.6 ± 4.0 mm) Width of trunk larger in females (5.6 ± 0.6 mm) than males (5.4 ± 0.9 mm)
Tuncer <i>et al.</i> , (2005)	80 MRI adult brain scans	Turkey	Larger rostrum in males Larger isthmus in males
Gupta <i>et al.</i> , (2008)	44 Formalin-preserved cadaver brains 30 MRI adult brain scans	India	Larger CC length in males (16.44 ± 1.04 cm) than in females (15.20 ± 0.82 cm)
Prendegrast <i>et al.</i> , (2015)	305 MRI brain scans	United States of America	Larger genu found earlier in males
Evidence against sexual dimorphism in CC morphology			
Bishop and Wahlstein (1997)	Review of 49 studies		Found that sex differences accounted for roughly 1% of variance in CC size between sexes
Ozdemir <i>et al.</i> , (2007)	92 MRI adult brain scans	Turkey	No sexual dimorphic differences observed
Luders <i>et al.</i> , (2014)	94 MRI adult brain scans	United States of America	No sexual dimorphic differences found when overall brain size was accounted for

1.6.2 Variability with age in the corpus callosum

It has been suggested that interhemispheric integrity is compromised in the elderly and this is due to loss of white matter with advancing age (Sungathy *et al.*, 2003). The generalized atrophy of cortical neurons affects distinct subregions of the CC differently (Sungathy *et al.*, 2003). MR imaging studies have shown that callosal features show modest thinning in cross sectional areas when viewed on a midsagittal section, with the thinning becoming more pronounced after the 6th decade of life (Ota *et al.*, 2006).

Common findings in the literature are described in Table 2 below. It can be seen that a general finding is that the genu decreases as individual's age and that the decrease is seen more profoundly in males than in females (Dubb *et al.*, 2003, Sungathy *et al.*, 2003, Prendergrast *et al.*, 2015). In a study conducted by Sungathy *et al.*, (2003) 100 MRI adult brain scans were measured. The sample was split into three age groups, which included 18 – 40, 41 – 60 and above 60 years of age. In the groups above 40 years it was found that the width of genu decreased (Sungathy *et al.*, 2003).

Prendergrast *et al.*, (2015) studied 305 MRI brain scans, and found that after the 3rd decade of life the width of genu decreased in males. The genu is involved in motor and selective attention, and loss of callosal integrity may underlie age as well as sex differences in interhemispheric communication (Bernard and Seidler, 2012). With age, there is an increase in the incidents of mirror movements and motor overflow (Bernard and Seidler, 2012). However, in one study conducted by Salat *et al.*, (1997) it was found that the females had a smaller genu with increasing age (Salat *et al.*, 1997).

Another general finding is that the splenium in females enlarges in relation to males with age (Dubb *et al.*, 2003, Gupta *et al.*, 2008). In a study conducted by Gupta *et al.*, (2008), 44 formalin preserved cadaver brains and 30 MRI adult brain scans were studied. After the 4th decade of life a larger splenium was observed in females (mean = 1.49 cm) than in males (mean = 1.18 cm). There was also a smaller CC mean width in older males (0.72 ± 0.17 cm) in comparison to younger males (0.91 ± 0.12 cm).

cm). It has been suggested that the larger splenium is due to a more lengthy development of the splenium in females than in males (Dubb *et al.*, 2003). In a study conducted by Sungathy *et al.*, (2003), 100 MRI adult brain scans were measured. The sample was split into 18 – 40, 41 – 60 and above 60 years of age. It was found that the length of CC increased in females over 40 years of age (Sungathy *et al.*, 2003).

In contrast, Sullivan *et al.*, (2001) found no age related changes in any of the CC parameters measured, which include the genu, corpus and splenium, as well as the length of the CC. This study stated that the CC remains stable over the adult age range, at least until 76 years of age (Sullivan *et al.*, 2001).

As discussed previously in Section 1.5.1, there is some controversy in the literature. This can be attributed to the same factors as described above. For example, there were definite sex and age related changes in a study conducted by Gupta *et al.*, (2008), however, the researchers did not account for brain size and that may have created a bias in their results.

Table 2: Age related variations in the literature

Study	Subjects	Population	Results
Evidence for age related variations in CC morphology			
Salat <i>et al.</i> , (1997)	76 Elderly MRI adult brains	United States of America	Smaller genu and anterior midbody in females with age ($p < 0.05$)
Dubb <i>et al.</i> , (2003)	189 MRI adult brain scans	United States of America	Larger splenium in females Smaller genu in males
Sungathy <i>et al.</i> , (2003)	100 MRI adult brain scans	India	Length of CC longer in older females Width of genu smaller in older males
Ota <i>et al.</i> , (2006)	42 MRI adult brain scans	Japan	Smaller rostrum, genu, anterior midbody and isthmus in older patients
Gupta <i>et al.</i> , (2008)	44 Formalin preserved cadaver brains 30 MRI adult brain scans	India	Larger splenium in older females (1.49cm) than in older males (1.18cm) Smaller CC width in older males (0.72 ± 0.17 cm) than younger males (0.90 ± 0.12 cm) Smaller genu in males with age
Lebel <i>et al.</i> , (2010)	315 MRI adult brain scans	Canada	Sharp reduction in size of genu across both sexes More gradual reduction in size in splenium across both age groups
Prendegast <i>et al.</i> , (2015)	305 MRI adult brain scans	United States of America	Width of genu smaller in older males Females reached peak width of genu later
Evidence against age related changes in CC morphology			
Sullivan <i>et al.</i> , (2001)	92 MRI adult brain scans	United States of America	No age related changes in any of the CC parameters measured

1.6.3 Mental disorders associated with alterations in the corpus callosum

As previously stated, the CC is the largest interhemispheric commissure and is responsible for many aspects of neural functioning, such as sensory, social and emotional processing (Bersani *et al.*, 2001, Fenlon and Richards, 2015). It has been observed in previous studies that even subtle deterioration of the CC subregions may diminish the transfer of information between the two hemispheres (Just *et al.*, 2007, Bersani *et al.*, 2011, Holleran *et al.*, 2014, Li *et al.*, 2014, Fenlon and Richards, 2015, Wang *et al.*, 2015). Cognitive impairments such as schizophrenia, bipolar disorder and depression show this type of deterioration (Fenlon and Richards, 2015). These impairments have been identified as mental disorders and can be classified according to DSM-5 and ICD 10 codes. However, in this study ICD 10 codes will be used as they are typically used in hospitals. The following scores will be used in order to select the CT scans to analyse and will include F20 (schizophrenia), F31 (bipolar disorder) and F33 (depression). CT scans have been shown to be applicable in the evaluation of patients with the abovementioned diseases (Wang *et al.*, 2015).

Schizophrenia is a serious mental disorder that is characterised by several abnormalities in different areas of mental functions, such as hearing in the form of auditory hallucinations, logical thinking in the form of thought disorders, as well as motivation and emotion (Ellison-Wright *et al.*, 2014). It has been proposed that schizophrenia is a disorder of anatomical connectivity and thus, locations of deficits in white fibre tracts may allow for the identification of the most critically affected tracts (Ellison-Wright *et al.*, 2014). This would provide targets for further neuroanatomical and functional studies (Ellison-Wright *et al.*, 2014). Table 3 below demonstrates the structural abnormalities in the CC found in the literature in patients diagnosed with schizophrenia. As can be seen, there is a decrease in the overall size of the CC and in the width of the genu in patients suffering from schizophrenia when compared to healthy controls (Höppner *et al.*, 2001, Colombo *et al.*, 1994, Collison *et al.*, 2014, Ellison-Wright *et al.*, 2014). A contradictory study by Chua *et al.*, (2000) found no differences in the length or size of the CC when compared to healthy controls.

Bipolar disorder is characterised by recurring episodes of extremely elevated, energized behaviour (manic behaviour) to periods of extremely low, hopeless behaviour (depressive behaviour) (Bellani *et al.*, 2009). They suggested that alterations in interhemispheric connectivity of bilateral homologous areas play a role in the progression of this disease. Bipolar disorders can be combined with studies conducted on schizophrenic patients, as it has been suggested that there is certain overlap amongst some of the symptomology (Li *et al.*, 2014). Table 4 describes the areas most affected in bipolar disorder namely: the genu, isthmus and splenium (Brambilla *et al.*, 2003, Li *et al.*, 2014). In a study by Brambilla *et al.*, (2003) 16 bipolar patients were compared with 27 healthy controls. It was found that the bipolar patients had a smaller length CC ($p < 0.05$) than the controls. In a study by Li *et al.*, (2014) 16 bipolar patients, 19 schizophrenic patients and 27 healthy controls were compared. It was found that the bipolar patients had a larger width of the genu than the schizophrenic patients, but both had smaller genu than the healthy controls. These areas are also affected in schizophrenia as described above. Thus, both disease show impaired emotional and cognitive processing. There are however differences that have been found between the two disorders. The most notable is the severity of the impairments and the overall prognosis being significantly worse in schizophrenic patients (Li *et al.*, 2014). These results are in contrast with a study by Matsuo *et al.*, (2009) where 20 bipolar disorder were compared with 27 healthy patients. They found no statistically significant differences in the various CC subregions.

Depression is a behavioural disorder in which the individual experiences distressing symptoms that affects how the individual feels and handles daily activities, sometimes interrupting said activities (Bae *et al.*, 2006). The main regions for mood control are located in the prefrontal cortex. It has been suggested that alterations in white matter connections of these regions may impair mood regulation and increase the risk of developing depression (Bae *et al.*, 2006). The results observed in the literature have been recorded in Table 3 below. In a study by Wu *et al.*, (1993) it was found that in patients suffering from depression, the genu and splenium were smaller than in controls ($p < 0.05$). They also reported that the patients had smaller CCs than the healthy controls. These results were consistent with a study by Bae *et al.*, (2006) in which it was found that depressive patients presented with a smaller genu and, as

a result, altering the connectivity between the two hemispheres. Lyoo *et al.*, (2002) observed a smaller genu and isthmus in patients when compared to controls ($p=0.005$ and $p=0.019$ respectively).

Alzheimer's disease is defined by neuronal loss, degeneration and atrophy of the cerebral cortex. This results in cognitive impairments and memory decline that interferes with social and behavioural functioning in patients (Duan *et al.*, 2005, Wang *et al.*, 2015). It has been suggested that the cognitive decline is a direct result of the deterioration of the functional connectivity between the two hemispheres via the CC (Wang *et al.*, 2015). As is shown in the literature in Table 6 below, a reduction in the size of the genu and splenium of the CC has been found in patients in relation to healthy controls (Teipel *et al.*, 2002, Duan *et al.*, 2005, Wang *et al.*, 2015). The genu and rostrum have been shown to be involved in memory and information retrieval from cortical association areas. Therefore, an abnormality in this area in patients can explain the memory difficulties which patients with Alzheimer's disease suffer from (Wang *et al.*, 2015).

There have been notable controversial results reported in the literature. A possible reason for this is that most of the studies have been performed on small samples, sometimes no more than 20 individuals suffering from a particular disorder. This can cause a slight bias to the results gained from the study as it is only a small representation of the overall population.

Table 3: Variations of schizophrenia in the literature

Schizophrenia			
Study	Subjects	Population	Results
Colombo <i>et al.</i> , (1994)	19 Schizophrenic patients	Italy	Reduced length of CC in patients
Woodruff <i>et al.</i> , (1995)	Comparison of 11 retrospective studies		Width of trunk increased in patients Decreased isthmus in patients Area of CC decreased by 0.5 cm ² in patients
Chua <i>et al.</i> , (2000)	35 Healthy controls (unrelated) 53 Healthy controls (family) 27 Schizophrenic patients	United States of America	No difference in length or size of subregions Schizophrenia not associated with abnormalities of the CC
Höppner <i>et al.</i> , (2001)	12 Healthy controls 12 Schizophrenic patients	Germany	Reduced length of CC in patients Smaller genu in patients
Collison <i>et al.</i> , (2014)	75 Healthy controls 125 Schizophrenic patients	United Kingdom	Reduced size of CC in patients Smaller anterior midbody and isthmus in patients
Ellison-Wright <i>et al.</i> , (2014)	21 Healthy controls 21 Schizophrenic patients	United Kingdom	Smaller genu and splenium in patients

Table 4. Variation of bipolar disorder in the literature

Bipolar Disorder			
Study	Subjects	Population	Results
Brambilla <i>et al.</i> , (2003)	16 Bipolar patients 27 Healthy controls	United States of America	Reduced length of CC in patients (p<0.05) Smaller genu, posterior midbody and isthmus in patients
Matsuo <i>et al.</i> , (2009)	20 Bipolar patients 27 Healthy controls	United States of America	No significant differences in CC subregions between patients and controls
Li <i>et al.</i> , (2014)	16 Bipolar patients 19 Schizophrenic patients 27 Healthy controls	China	Reduced size in genu, isthmus and splenium in both BD and SZ patients compared to controls (p<0.05) BD patients had larger posterior genu than SZ patients

Table 5. Variations of depression in the literature

Depression			
Study	Subjects	Population	Results
Wu <i>et al.</i> , (1993)	20 depressed patients 16 healthy controls	United States of America	Smaller genu and splenium in patients ($p < 0.05$) Reduced length CC in patients
Lyoo <i>et al.</i> , (2002)	40 female depressed patients 42 female healthy controls	South Korea	Smaller genu observed in patients ($P = 0.005$) Smaller isthmus observed in patients ($p = 0.019$)
Bae <i>et al.</i> , (2006)	106 elderly depressed patients 86 elderly healthy controls	South Korea	Smaller genu observed in depressive patients than in healthy controls

Table 6. Variations of Alzheimer's disease in the literature

Alzheimer's Disease			
Study	Subjects	Population	Results
Teipel <i>et al.</i> , (2002)	21 Alzheimer's patient 10 Healthy controls	United States of America	Smaller genu in patients (< 0.02) Reduction in size of isthmus and splenium in patients (< 0.001)
Duan <i>et al.</i> , (2005)	16 Alzheimer's patients 12 Healthy controls	China	Smaller size in splenium of corpus callosum (< 0.001)
Wang <i>et al.</i> , (2015)	20 Retrospective studies		Consistently found a reduction in genu and splenium of CC in patients

1.7 Possible reasons for contradictions in the literature

The controversy in regard to whether or not differences in CC morphology exist between sexes and various age groups as well as in individuals who suffer from mental disorders, can be due to various factors.

The CC is an anatomical structure and it has been shown that a certain degree of individual variation exists which can distinctly change its shape and size (Reinoso-Barbero *et al.*, 2014).

Another reason may be due to resolution of the CT and MRI scans. With these, the dimensions often are underestimated as boundaries cannot always be clearly delineated due to either the resolution of the scan, the patient having moved or the presence of a soft tissue interface (Höhne and Hanson, 1992).

With cadaver studies, there is a shrinkage factor (Schoeman, 2016).

Another factor that can influence the results would be the method used to partition the CC for measurement. There are various techniques that are used, with each one having unique methodologies in order to segment the subregions of the CC (Witelson, 1989, Allen *et al.*, 1991, Ryberg *et al.*, 2006). As a result, depending on which part of the CC that is being measured, a bias to be introduced.

Small sample size could also lead to conflicting results. For instance, if a group is small then outliers will have a greater impact on the mean of the sample. In other words, if a particular group is only made up of the extremes of the sample, then it will prejudice the results towards the extreme rather than giving the overall average.

There is therefore a need for standardized measuring techniques to be used in order to ensure repeatability of studies. Most of the studies that measure the CC are done on American (Salat *et al.*, 1997, Sullivan *et al.*, 2001, Dubb *et al.*, 2003, Lebel *et al.*, 2010, Luders *et al.*, 2014, Prendegast *et al.*, 2015), European (Tuncer *et al.*, 2005, Ozdemir *et al.*, 2007) or Asian (Sungathy *et al.*, 2003, Ota *et al.*, 2006, Gupta *et al.*,

2008) populations, with one study being conducted on a South African population to the author's knowledge (Constant and Ruther, 1996).

Each region of the world has unique environmental pressures that could influence the physical development of its populace (Eberhardt, 2005) and information that is gathered in previous studies conducted in foreign populations cannot be extrapolated onto a South African population, as this could/would suggest inaccuracies.

2 Aims and Objectives

2.1 Aims

The aim of this study was to provide a detailed description of the anatomy and variations of the corpus callosum morphology in a South African population. A primary data set was compiled using a cadaveric population and these results were compared to a secondary data set from a healthy living population. Lastly, the results from both data sets were then compared with a third data set comprising of a mental disorder population and results gained from previous studies, in order to determine possible diagnoses of certain mental disorders based on CC morphology.

2.2 Research Objectives

The research objectives were implemented on all three data sets and were:

1. To determine whether a difference exists in the CC anatomy between females and males.
2. To investigate whether a relationship exists between variations in the CC morphology and the age of the individual.
3. To determine the size of the CC relative to whole brain size.
4. To determine whether a difference exists between the CC parameters of the three mental disorders examined.
5. To determine whether a difference exists in the CC parameters measured between cadaveric, healthy and mental disorder imaging samples.
6. To compare these results with those in the literature in order to determine a data set for diagnosing associated diseases specific to the South African population.

3 Materials and Methods

3.1 Ethical Clearance

Ethical clearance for this study was obtained from the Faculty of Health Sciences Research Ethics Committee at the University of Pretoria (379/2016). Approval was given from the Department of Anatomy at the University of Pretoria, University of Witwatersrand and Sefako Makgatho Health Sciences University for the use of cadavers. The use of cadavers falls under the South African National Health Act 61 of 2003. Approval was granted from the Head of Radiology at Muelmed Mediclinic Hospital in Pretoria in order to use the MRI scans of previous patients. Approval was granted for use of CT scans of patients previously diagnosed with specified mental disorders from the Head of Radiology at Kalafong Hospital in Pretoria.

3.2 Study design

The data in this study was collected from a cadaveric and living sample, which was further divided into a healthy and mental disorder sample. Thus, the study was divided into three parts with each part involving a unique sample and method of collecting the data. A quantitative analytical study design was used. The cadaver part of the study was conducted in the Anatomy Departments of the University of Pretoria, University of Witwatersrand and Sefako Makgatho Health Sciences University. The healthy imaging part of the study was conducted in the Department of Radiology at Muelmed Mediclinic Hospital. The mental disorder imaging part of the study was conducted in the Department of Radiology at Kalafong Hospital. The shape of the splenium was observed and recorded whether it was bulbous or tubular. The presence of an isthmus was noted and recorded.

The variability in the anatomy of the CC was examined in a BSc (Hons) pilot study. In the current study it was noted that the areas that showed the most variation with regard to sex and age was the thickness of the genu, splenium and corpus. It was also found that, in order to accurately describe a sexual dimorphic difference, whole brain size had to be accounted for that required to measure the length of the CC. Thus, in order to address the first and second objective for all samples, certain

measurements were made using the parameters set out in the pilot study. Witelson's (1989) method of partitioning the CC was used for the cadaveric and both living samples. The CC was divided into halves, thirds and a posterior one fifth as demonstrated in Figure 5 below. This allows for seven subregions to be identified; the rostrum, the genu, the rostral body, the anterior midbody, the posterior midbody, the isthmus and the splenium of the CC.

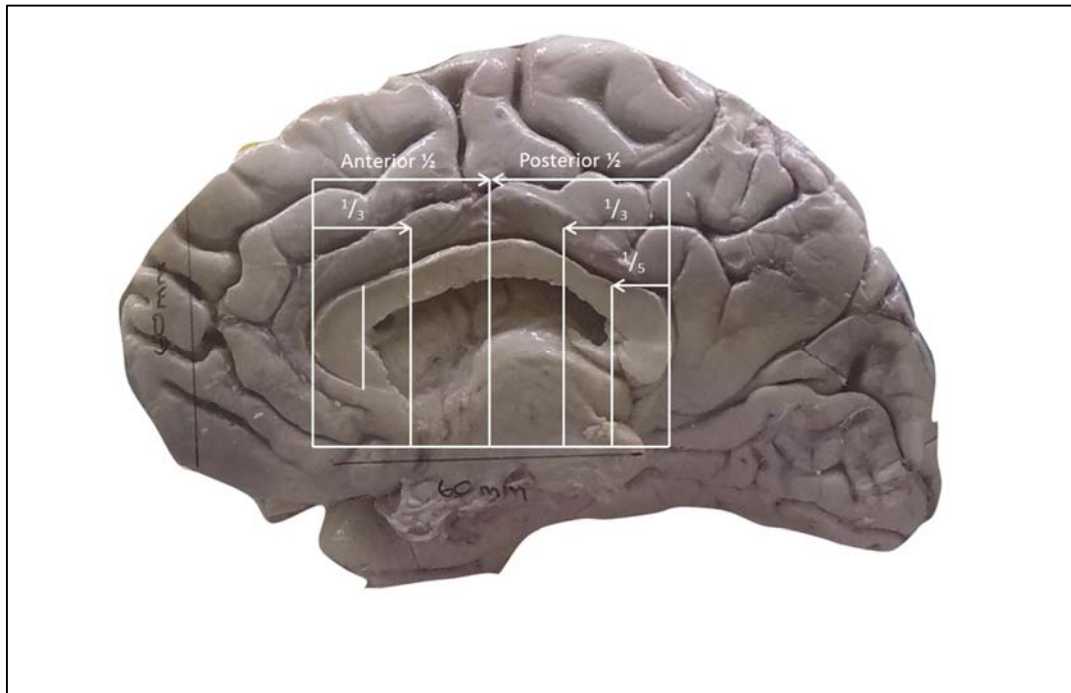


Figure 5. Cadaver brain demonstrating the Witelson method of partitioning

The measurements were taken in the genu, anterior and posterior midbody and the splenium of the CC. The dimensions are defined as described in Table 7 below. In order to address the third objective, a ratio was defined which assumed a simple linear relationship between the CC and the whole brain size for all subjects. This expresses each individual's CC measurement relative to their intracranial volume.

Table 7: Measurements that were taken of the CC

Measurements		
	Parameter name	Description
TG	Thickness of genu	Distance from the anterior most point of the genu to the posterior most point of the CC concavity
TS	Thickness of splenium	Vertical distance of the splenium at its widest point
TT	Thickness of corpus	Vertical distance of the CC corpus at its widest point
LC	Length of the CC	Straight line distance between the anterior most point of the genu to the posterior most point of the splenium
LB	Length of cerebrum	Distance between the anterior most point of the frontal lobe to the posterior most point of the occipital lobe
Ratio		
LC/LB		Length of the CC relative to the length of the whole brain

3.3 Procedures and criteria for selection

3.3.1 *Cadaver study*

Seventy-one brains were harvested from preserved cadavers for use in the dissection halls in the Anatomy departments of the University of Pretoria, University of Witwatersrand and the Sefako Makgatho Health Sciences University; 53 in 2016 and 19 in 2017. The demographic information related to each cadaver was obtained from the University records; sex and age were required for this study. The cadavers were divided into subgroups of 41 males and 30 females, and only included adult cadavers over the age of 18 years. Other factors such as height, weight and race were not a reason for exclusion from this study. Cadavers with known or visible pathology or surgery to the cerebral hemisphere and brains that were poorly preserved were also excluded.

The brains were removed from the cadavers during the dissection practicals of the third-year medical science and second year medical and dental students in the Departments of Anatomy. Midsagittal sections were then made using a brain knife once the arachnoid was cleaned from the surface. Half of the brain was recorded using the following procedure. A GoPro Hero 4 Black wide angle 12.0 megapixel digital camera was placed on a tripod on the dissection table. The camera was

pointed straight and downward 30 cm from the top of the dissection table. A scale bar was placed directly on top of the cadaver brains. Photographs were taken and downloaded onto a desktop computer. Images were unpaired and digital photographs were imported into the AutoCAD 2015 edition software.

Due to the conflicting results reported in the literature, the measurements were standardized in order to assure repeatability. When measuring the brains in AutoCAD 2015, the Snap Tools feature was enabled. This is a feature that was designed in order to compensate for human factors such as point precision, hand movement and fatigue in virtual design programmes (Fiorentino, 2004). Snap Tools are drawing aids that enhance the user's accuracy when using an imprecise input device, such as a mouse, on a computer. These tools constrain the user to sketch lines that are horizontal, vertical or perpendicular to the screen directions (Fiorentino, 2004). This allows for the user to accurately draw straight, vertical and horizontal lines. Another feature of Snap Tools allows the user to 'snap' onto a specific object location in relation to its position to a specified point (Fiorentino, 2004). Allowing for the midpoint of a vertical or horizontal line to be accurately defined. Snap Tools was enabled for all CC measurements performed on all three data sets.

Thus, when measuring the genu (TG), a vertical line was drawn at the most anterior point of the CC and another vertical line was drawn at the most posterior point of the genu. The horizontal distance between the two vertical lines was then measured to determine the thickness of the genu. See Figure 6 below for the standardized measurements.



Figure 6. Standardized measurement of the genu

The thickness of the splenium (TS) was determined by first drawing a horizontal line at the widest point of the splenium. The midpoint of that line was then determined using Snap Tools, and the vertical distance from the most inferior point of the splenium to the most superior point was then measured. See Figure 7 for standardized measurements for the splenium.



Figure 7. Standardized measurement of the splenium

The thickness of the corpus or trunk (TT) was determined by first drawing a horizontal line that connected the anterior most point of the CC with the posterior most point of the CC. The midpoint of that line was then determined using Snap Tools. A vertical line was drawn from the midpoint of the horizontal line to the most superior point of the corpus or trunk. The vertical distance from the most superior point of the line to the most inferior point of the corpus or trunk was then measured. See Figure 8 below for the standardized measurements.




Figure 8. Standardized measurement of the corpus or trunk

The length of the CC (LC) was measured by firstly drawing a vertical line at the most anterior point of the CC and secondly another vertical line at the most posterior point of the CC. The two vertical lines were then connected with a horizontal line and the horizontal distance was measured. See Figure 9 below for the standardized measurements.



Figure 9. Standardized measurement of the CC

The length of the cerebrum (LB) was measured by first drawing two vertical lines, one at the most anterior point of the cerebrum and the other at the most posterior point of the cerebrum. The two vertical lines were connected with a horizontal line and the horizontal distance was measured. See Figure 10 below for the standardized measurements.

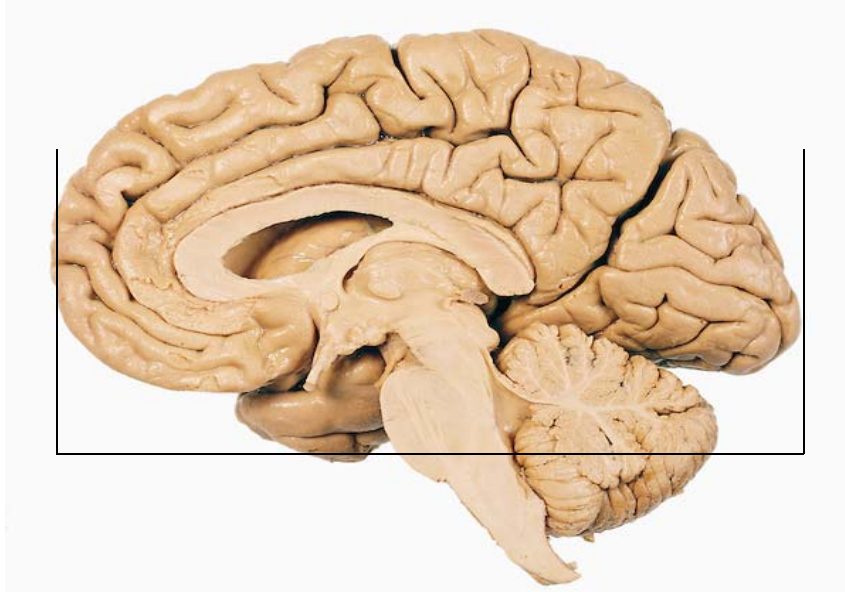


Figure 10. Standardized measurement of the cerebrum

3.3.2 Imaging study – healthy

One hundred and twenty-seven MRI scans were retrospectively selected for analysis from the imaging database at the Department of Radiology, Muelmed Mediclinic Hospital. MRI scans were used due to the availability of the scans at the hospital. The demographic information, related to each patient, was obtained from the scan and included sex and age. Each patient was given a reference number and it was associated with the demographic information in order to protect the individual's identity. The images were divided into subgroups of 51 males and 76 females, and only included healthy adult individuals over the age of 18 years. Other factors such as height, weight and race were not a reason for exclusion from this study. Only scans from individuals who have not undergone surgery nor have any pathology that affects the corpus callosum were used.

In order to ensure the standardization of the measurements the Digital Imaging and Communications in Medicine (DICOM) files were imported into AutoCAD 2015 edition. The Snap Tools feature was enabled for all healthy MRI scans in order to accurately measure the images. When measuring the genu (TG), a vertical line was drawn at the most anterior point of the CC and another vertical line was drawn at the most posterior point of the genu. The horizontal distance between the two vertical lines was then measured. See Figure 11 below for the standardized measurements.

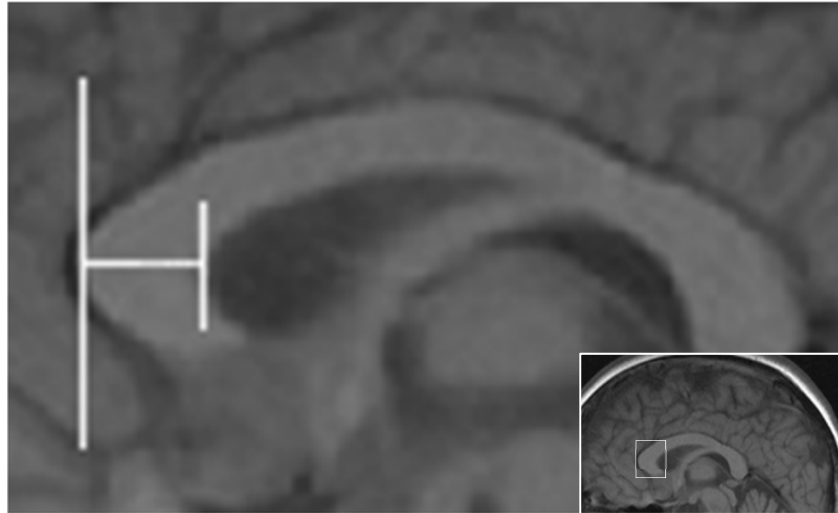


Figure 11. Standardized measurement of the genu

The thickness of the splenium (TS) was determined by first drawing a horizontal line at the widest point of the splenium. The midpoint of that line was then determined using Snap Tools, and the vertical distance from the most inferior point of the splenium to the most superior point was then measured. See Figure 12 for standardized measurements for the splenium.

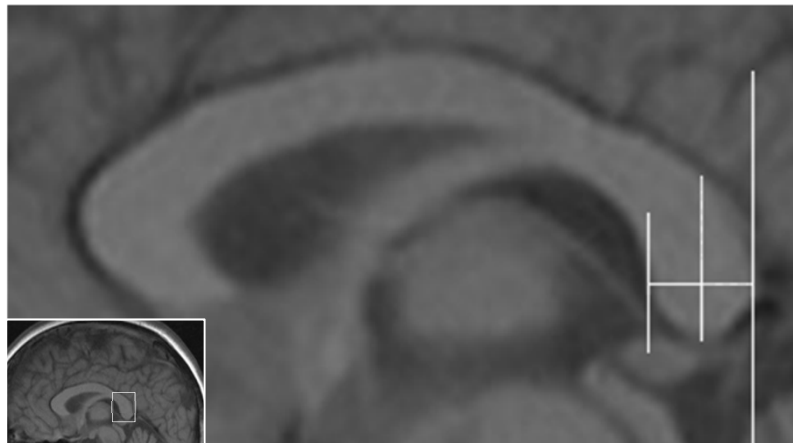


Figure 12. Standardized measurement of the splenium

The thickness of the corpus or trunk (TT) was determined by first drawing a horizontal line that connected the anterior most point of the CC with the posterior most point of the CC. The midpoint of that line was then determined using Snap Tools. A vertical line was drawn from the midpoint of the horizontal line to the most superior point of the corpus or trunk. The vertical distance from the most superior

point of the line to the most inferior point of the corpus or trunk was then measured. See Figure 13 below for the standardized measurements.

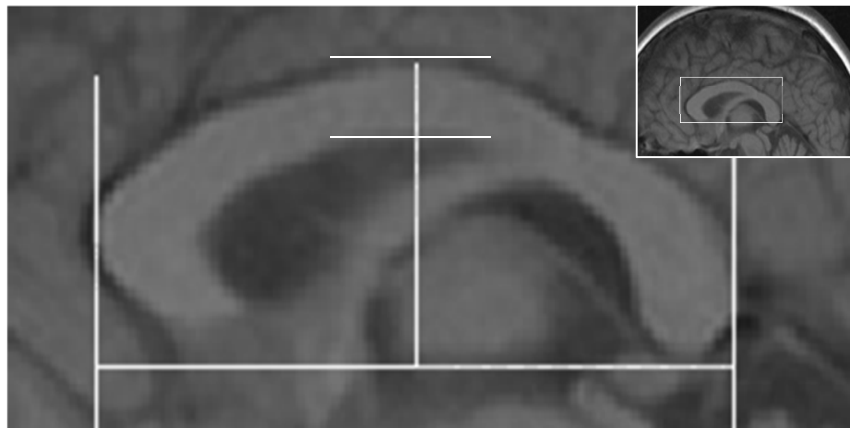


Figure 13. Standardized measurement of the corpus or trunk

The length of the corpus (LC) was measured by first drawing a vertical line at the most anterior point of the CC and another vertical line at the most posterior point of the CC. The two vertical lines were then connected with a horizontal line and the horizontal distance was measured. See Figure 14 below for the standardized measurements.

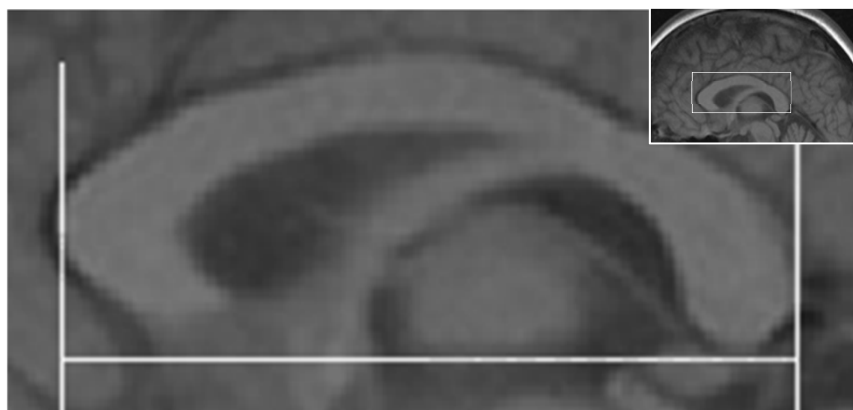


Figure 14. Standardized measurement of the CC

The length of the cerebrum (LB) was measured by first drawing two vertical lines, one at the most anterior point of the cerebrum and the other at the most posterior point of the cerebrum. The two vertical lines were connected with a horizontal line and the horizontal distance was measured. See Figure 15 below for the standardized measurements.

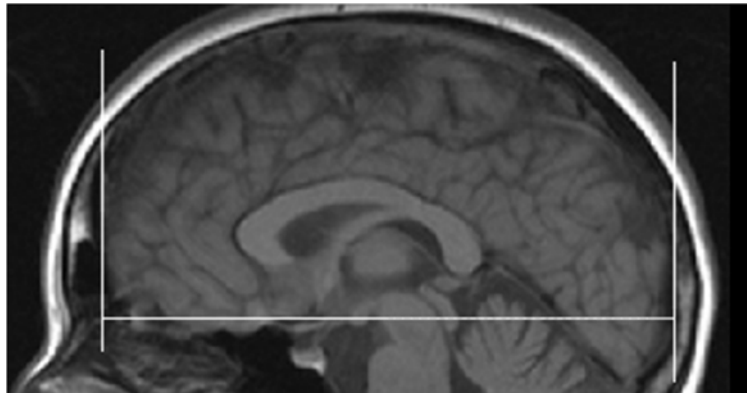


Figure 15. Standardized measurement of the cerebrum

3.3.3. Imaging study – mental disorders

Sixty-three pre- and post-contrast CT scans were retrospectively selected for analysis from the imaging database at the Department of Radiology, Kalafong Hospital. This hospital did not take MRI scans of their patients and only CT scans of the patients were available for the psychiatric sample. The scans were of individuals who have been classified as those suffering from schizophrenia, bipolar disorder and/or depression according to the DSM-5 and ICD 10 codes. The sample comprised of ten schizophrenic patients, nine bipolar patients, eight cognitive deficit patients, seven depressive patients and twenty-three patients suffering from psychosis. There were five patients who suffered from disorders not stated above. The images were divided between the sexes, 42 males and 21 females. Only individuals over the age of 18 years were included in this study. Other factors such as height, weight and race were not a reason for exclusion from this study. Only scans from individuals who have not undergone surgery nor have any other pathology that affects the corpus callosum were used.

In order to ensure the standardization of the measurements the Digital Imaging and Communications in Medicine (DICOM) files were imported into AutoCAD 2015 edition. The Snap Tools feature was enabled for all mental disorder CT scans in order to accurately measure the images. When measuring the thickness of the genu (TG), a vertical line was drawn at the most anterior point of the CC and another vertical line was drawn at the most posterior point of the genu. The horizontal

distance between the two vertical lines was then measured. See Figure 16 below for the standardized measurements.

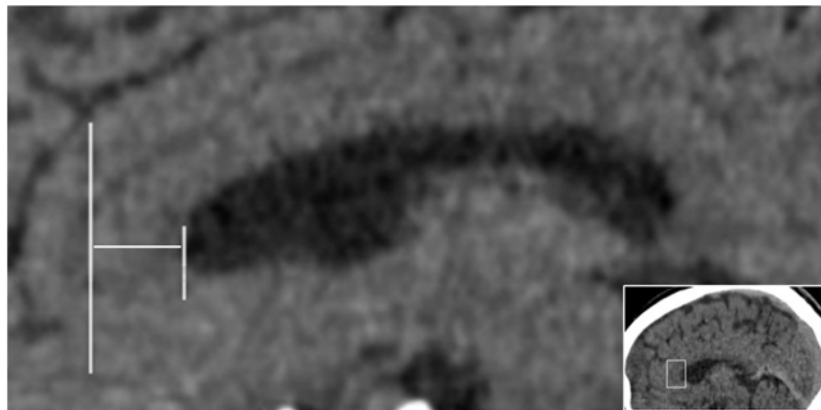


Figure 16. Standardized measurement of the genu

The thickness of the splenium (TS) was determined by first drawing a horizontal line at the widest point of the splenium. The midpoint of that line was then determined using Snap Tools, and the vertical distance from the most inferior point of the splenium to the most superior point was then measured. See Figure 17 for standardized measurements for the splenium.

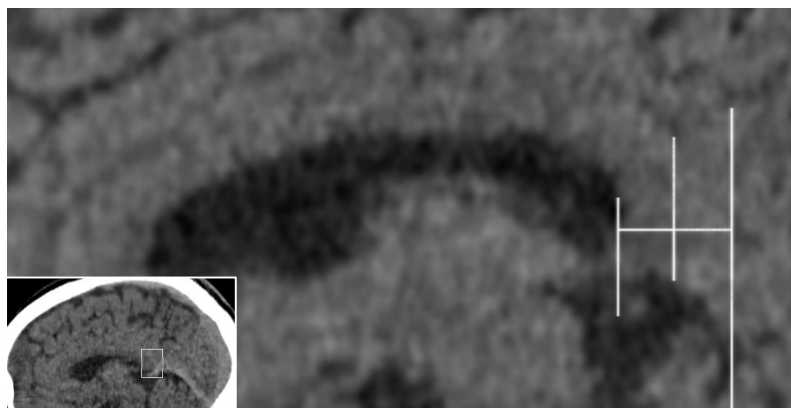


Figure 17. Standardized measurement of the splenium

The thickness of the corpus or trunk (TT) was determined by first drawing a horizontal line that connected the anterior most point of the CC with the posterior most point of the CC. The midpoint of that line was then determined using Snap Tools. A vertical line was drawn from the midpoint of the horizontal line to the most superior point of the corpus or trunk. The vertical distance from the most superior

point of the line to the most inferior point of the corpus or trunk was then measured. See Figure 18 below for the standardized measurements.

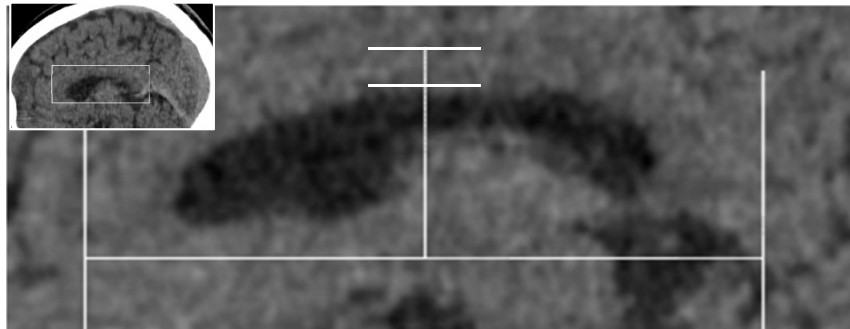


Figure 18. Standardized measurement of the corpus

The length of the corpus (LC) was measured by first drawing a vertical line at the most anterior point of the CC and another vertical line at the most posterior point of the CC. The two vertical lines were then connected with a horizontal line and the horizontal distance was measured. See Figure 19 below for the standardized measurements.

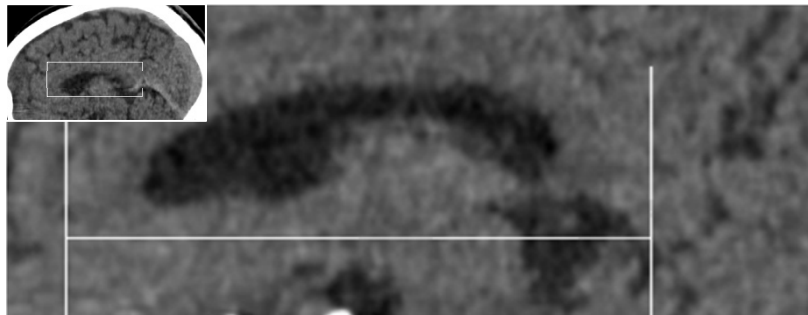


Figure 19. Standardized measurement of the CC

The length of the cerebrum (LB) was measured by first drawing two vertical lines, one at the most anterior point of the cerebrum and the other at the most posterior point of the cerebrum. The two vertical lines were connected with a horizontal line and the horizontal distance was measured. See Figure 20 below for the standardized measurements.

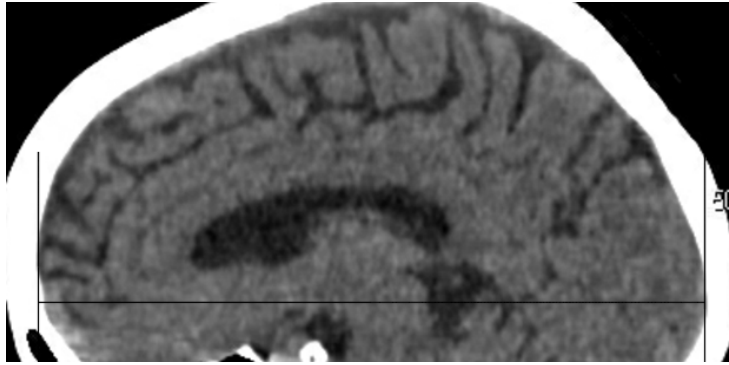


Figure 20. Standardized measurement of the cerebrum

3.4. Statistical analyses

IBM SPSS Statistics version 20 was used for the statistical analysis. Descriptive statistics were used to describe the shape and size of the CC anatomy. These included the mean, standard deviation (SD), maximum and minimum values. Comparisons between the males and females were made using a paired t-test. The homogeneity of the variances was tested using a Levene's test.

A Multivariate Analysis of Variances (MANOVA) test was performed in order to determine if there was a statistically significant ($p < 0.05$) difference between the dependent variables (measurements of the CC parameters) and the independent variables (various age groups). A MANOVA test does not demonstrate which of the groups are different from one another, only that there was a statistically significant difference between the variables. In order to determine which of the groups are different, post hoc tests need to be performed. In this study, a Scheffe's comparison test was performed in order to determine which of the variables were significantly different ($p < 0.05$) from one another.

A Pearson's correlation test was performed to determine the linear relationship between the dependant and independent variables, i.e. if the measurements of the CC increase or decrease as the age increases and according to sex of the individual. A r-value between 0.75 and 1.0 indicates a high (strong) correlation between the independent variables and the measure distance(s), a moderate correlation will have a r-value between 0.5 and 0.74, while any r-value less than 0.5 will be considered as

a poor correlation. A Spearman's correlation test was performed to determine the monotonic relationship between the dependant and independent variables.

In the samples, the dependant variables were the measurements of the various subregions of the CC, while the independent variables were the sex and age of the individuals.

The same statistical tests as described above were performed on the healthy and mental disorder imaging sample.

A one- way Analysis of Variance (ANOVA) was used to determine if there was a difference between any of the measurements (i.e thickness of genu etc) between the cadaver, healthy and mental disorder sample. A one-way ANOVA tests the means of the three samples in order to determine if there was a statistically significant ($p < 0.05$) difference. This test does not determine which of the three groups are different, only that there was a difference. In order to determine which of the groups differed from one another, post hoc tests were also performed.

4. Results

4.1 Cadaver study

Figure 21 represents the sex distribution of the cadaver sample. Measurements were taken on 71 cadaver brains, 30 females and 41 males.

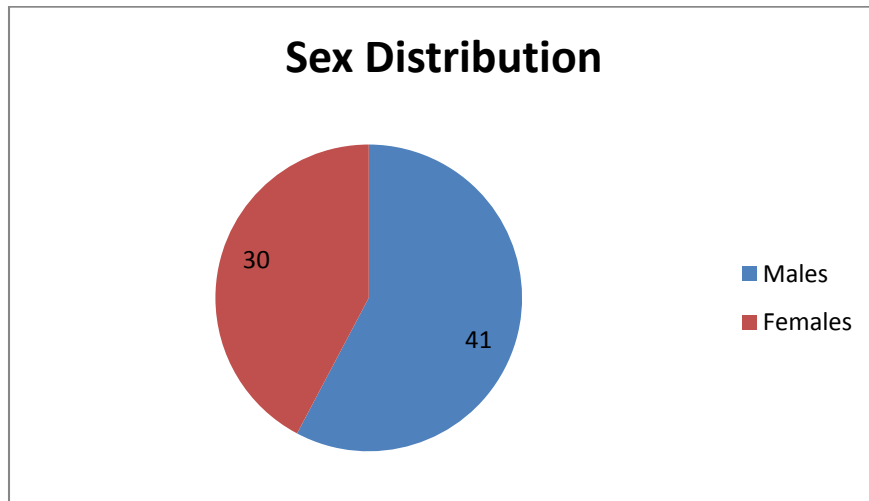


Figure 21. Sex distribution of cadaver sample

Figure 22 shows the age distribution among the female cadavers (n=30) of the cadaver sample. There was one individual where the age was unknown. That individual was included in the comparison between the sexes, but not in the age comparisons. As shown in Table 5 below, the maximum age was 95 years and the minimum age was 34 years. The mean age for the female cadavers was 74.9 ± 15.7 years.

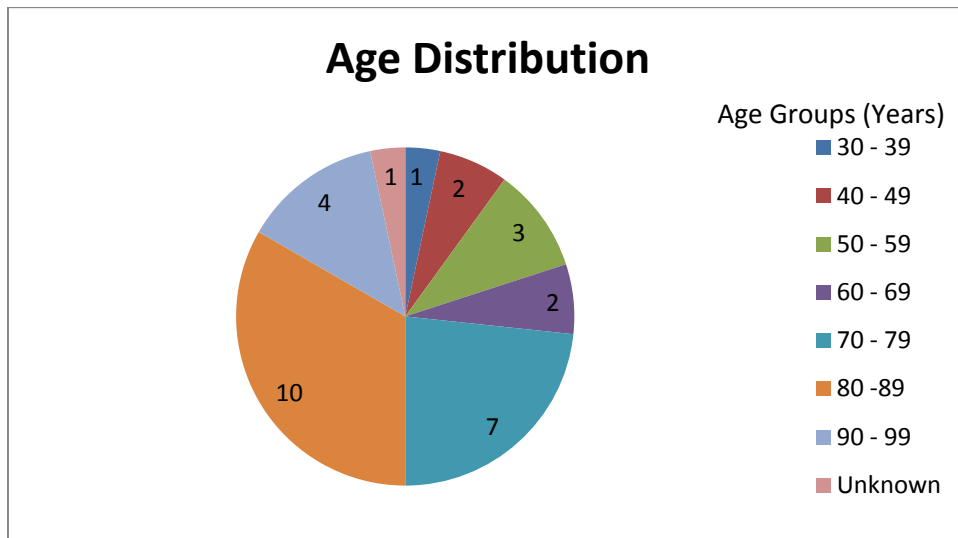


Figure 22. Age distribution of female cadaver sample

Figure 23 below shows the age distribution among the male cadavers (n=41). There were 5 individuals whose ages were unknown. Those individuals were included in the comparison between the sexes but were not included in the age comparisons. As seen in Table 6 below, the maximum age was 92 years and the minimum age was 26 years. The mean age for the male cadavers was 66.8 ± 16.7 years.

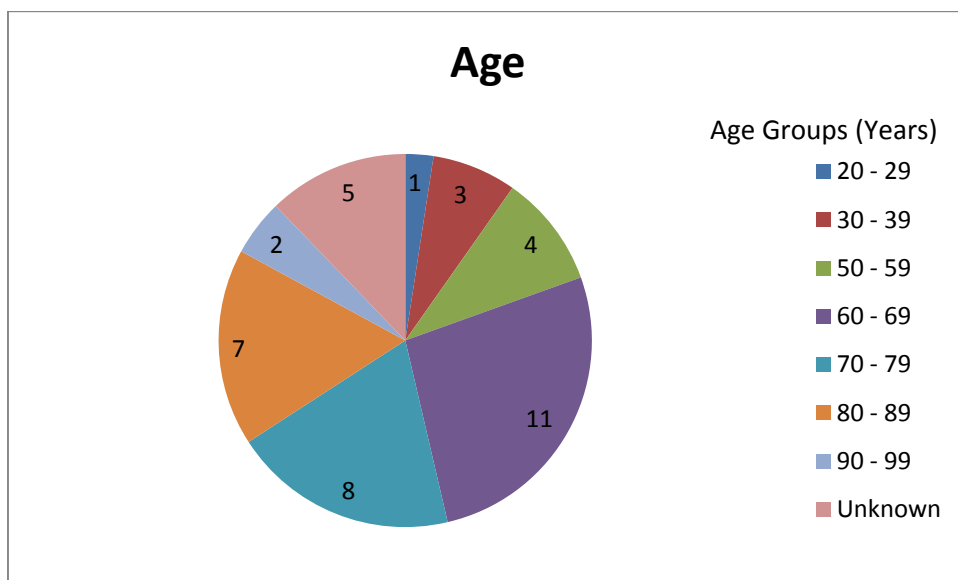


Figure 23. Age distribution of male cadaver sample

Table 8 shows the descriptive statistics for specific parameters of the CC in the female cadaver sample. Measurements were the thickness of the genu (TG), the vertical thickness of the splenium (TS), the thickness of the corpus or trunk (TT), the

length of the CC (LC) and the length of the cerebrum (LB). A ratio of length of CC (LC) to the length of the cerebrum (LB) was also calculated in order to demonstrate if the size of the measurements was affected by the size of the brain. As can be seen below the mean value of the ratio was 2.1 ± 0.2 in the female cadaver sample.

Table 8. Descriptive statistics of female cadaver sample

	N	Minimum (mm)	Maximum (mm)	Mean (mm)	SD (mm)
Age	29	34	95	74.9	15.7
TG	30	6.8	13.9	10.6	1.6
TS	30	10.0	21.3	16.2	2.7
TT	30	4.2	8.4	6.4	0.9
LC	30	56.3	83.0	71.4	5.8
LB	30	134.5	164.5	150.7	6.5
Ratio	30	1.8	2.6	2.1	0.2

Table 9 shows the descriptive statistics for the specific parameters of the CC in the male cadaver sample. Measurements were the thickness of the genu (TG), the vertical thickness of the splenium (TS), the thickness of the corpus or trunk (TT), the length of the CC (LC) and the length of the cerebrum (LB). A ratio of length of CC (LC) to the length of the cerebrum (LB) was also calculated in order to demonstrate if the size of the CC was affected by the size of the brain. As can be seen the ratio was 2.2 ± 0.2 in the male cadaver sample.

Table 9. Descriptive statistics of male cadaver sample

	N	Minimum (mm)	Maximum (mm)	Mean (mm)	SD (mm)
Age	36	26	92	66.8	16.7
TG	41	8.3	13.2	10.5	1.4
TS	41	9.2	22.6	16.2	2.5
TT	41	2.9	8.6	6.5	1.2
LC	41	55.7	80.8	72.3	5.2
LB	41	148.4	168.1	156.6	5.7
Ratio	41	1.9	2.7	2.2	0.2

Figure 24 shows a comparison between the mean measurements for the parameters measured between the sexes.

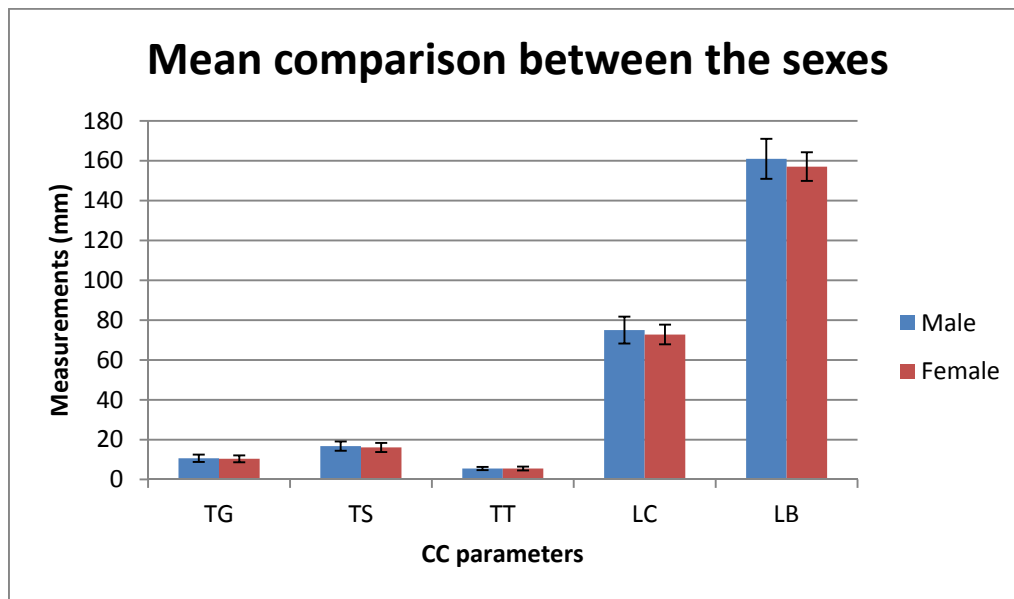


Figure 24. Mean comparison of CC parameters between the sexes

Due to the unequal distribution among the age groups, the age groups were pooled. In the female cadaver sample individuals whose ages were between 18 to 39 years were grouped together in the 18 – 39 category (n=1). There was only one individual in the 18 – 39 category for the females cadaver sample, thus, there was no standard deviation for that age group. Individuals whose ages were between 40 to 59 years were grouped together in the 40 – 59 category (n=5). Individuals whose ages were between 60 to 99 years were grouped together in the 60 – 99 category (n=23). Table 10 below demonstrates the mean and standard deviation of the CC measurements amongst the various age groups described above in the female cadaver sample.

Table 10. Descriptive statistics of various age groups for female cadaver sample

Age Group (years)		TG (mm)	TS (mm)	TT (mm)	LC (mm)	LB (mm)
18 - 39	Mean	11.00	17.60	7.00	74.80	153.10
	SD	-	-	-	-	-
40 - 59	Mean	11.54	17.82	6.74	70.94	150.92
	SD	1.36	2.78	1.21	6.46	10.32
80 -99	Mean	10.36	15.64	6.22	71.40	150.32
	SD	1.65	2.43	0.93	5.89	5.89

Due to the fact that in some of the age groups there were less individuals, the age groups were joined together in order to have a more accurate group comparison. In the male cadaver sample individuals whose ages were between 18 to 39 years were grouped together in the 18 - 39 category (n=4). Individuals whose ages were between 40 to 59 years were grouped together in the 40 - 59 category (n=4). Individuals whose ages were between 60 to 99 years were grouped together in the 60 – 99 category (n=28). Table 11 below demonstrates the mean and standard deviation of the CC measurements amongst the various age groups described above in the male cadaver sample.

Table 11. Descriptive statistics of various age groups for male cadaver sample

Age Group (years)		TG (mm)	TS (mm)	TT (mm)	LC (mm)	LB (mm)
18 - 39	Mean	11.03	17.43	6.50	69.55	156.73
	SD	1.21	3.51	1.81	9.28	6.59
40 - 59	Mean	10.36	17.33	6.78	71.76	153.73
	SD	1.06	1.31	0.88	4.96	5.19
80 -99	Mean	10.29	15.43	6.31	72.38	156.10
	SD	1.44	2.24	1.32	4.66	5.41

An independent t-test was performed on the female and male samples in order to determine whether there was a significant difference between the parameters measured in the two sexes. The results are shown in Table 12 below. Levene's test for equality of variances was performed in order to determine the homogeneity of the standard deviation between the sexes. A p-value of >0.05 was recorded for the measurements of the genu (TG) (p=0.75), splenium (TS) (p=0.57), corpus or trunk

(TT) ($p=0.14$), length of the CC (LC) ($p=0.63$) and length of the cerebrum (LB) ($p=0.84$). Thus, the equality of variances can be assumed for the male and female cadaver sample.

Table 12. Mean comparison between the sexes of the cadaver sample

		Levene's Test for Equality of Variances		t-test for Equality of Means		
		F	Sig.	t	df	Sig. (2-tailed)
TG	Equal variances assumed	0.10	0.75	0.55	63	0.59
	Equal variances not assumed			0.54	55.1	0.59
TS	Equal variances assumed	0.33	0.57	0.36	63	0.72
	Equal variances not assumed			0.36	58.3	0.72
TT	Equal variances assumed	2.23	0.14	-0.16	63	0.88
	Equal variances not assumed			-0.16	62.6	0.87
LC	Equal variances assumed	0.24	0.63	-0.41	63	0.69
	Equal variances not assumed			-0.40	56.4	0.69
LB	Equal variances assumed	0.04	0.84	-6.62	63	0.00
	Equal variances not assumed			-3.55	54.4	0.00

As can be seen there is no significant difference ($p > 0.05$) for the thickness of the genu (TG) ($p = 0.59$), splenium (TS) ($p = 0.72$), trunk (TT) ($p = 0.88$) and length of the CC (LC) ($p = 0.69$) between the sexes. However, there is a significant difference between the length of the brain (LB) ($p = 0.00$) between the two sexes.

A MANOVA test was performed in order to determine if there was a significant difference between the parameters measured for the different age groups. Table 13 below shows that differences between the groups. There was no significant difference ($p>0.05$) for the thickness of the genu (TG) ($p=0.30$), thickness of the trunk (TT) ($p=0.46$), length of the CC (LC) ($p=0.85$) and length of the cerebrum (LB) ($p=0.56$) between the various age groups. However, there was a significant difference ($p=0.02$) in the thickness of the splenium (TS) between the various age groups.

Table 13. Mean comparison amongst various age groups

Source	Dependent Variable	df	F	Sig.
Age Groups	TG	2	2.19	0.30
	TS	2	4.35	0.02
	TT	2	0.80	0.46
	LC	2	0.14	0.85
	LB	2	0.13	0.56

A Scheffe's comparison was then performed in order to determine which groups differed from one another; the results are shown in Table 14 below. There was a significant difference observed in the thickness of the splenium (TS) only. It was demonstrated that the difference was between the 40 – 59 and 60 - 99 age group, however, this difference was just above the statistically significant level ($p=0.06$). Thus, the difference is not significant. There was no statistically significant difference observed in any of the other subregions.

Table 14. Scheffe's test amongst various age groups

Dependent Variable	Age Groups	Age Groups	Sig.
TG	18 – 39	40 – 59	1.00
		60 – 99	0.60
	40 – 59	18 – 39	1.00
		60 – 99	0.43
TS	18 – 39	40 – 59	0.94
		60 – 99	0.21
	40 – 59	18 – 39	0.94
		60 – 99	0.06
TT	18 – 39	40 – 59	0.97
		60 – 99	0.83
	40 – 59	18 – 39	0.97
		60 – 99	0.51
LC	18 – 39	40 – 59	0.97
		60 – 99	0.88
	40 – 59	18 – 39	0.97
		60 – 99	0.95
LB	18 – 39	40 – 59	0.56
		60 – 99	0.72
	40 – 59	18 – 39	0.56
		60 – 99	0.86

A Pearson's correlation test was performed in order to determine if there was a relationship between the dependent variables (age and sex of the cadaver) and the independent variables (collected measurements of the various parameters). The results from the Pearson's correlation are shown in Table 15 below. As can be seen there is a weak negative correlation for the thickness of the genu (TG) ($r=-0.18$), the thickness of the splenium (TS) ($r=-0.31$), thickness of the trunk (TT) ($r=-0.13$) and length of the cerebrum (LB) ($r=-0.07$) with age. There is a weak positive correlation ($r=0.06$) with the length of the CC (LC) with age. As can be seen there is a weak negative correlation for the thickness of the genu (TG) ($r=-0.07$) and thickness of the splenium (TS) ($r=-0.05$) with sex. There is a weak positive correlation thickness of the trunk (TT) ($r=0.02$), the length of the CC (LC) ($r=0.05$) and length of the cerebrum

(LB) ($r=-0.07$) with sex. All these correlations are considered weak as the r-value is less than 0.5.

Table 15. Pearson's correlation of the cadaver sample

		TG	TS	TT	LC	LB
Age	r-value	-0.18	-0.31	-0.13	0.07	-0.05
	Sig. (2-tailed)	0.15	0.01	0.30	0.56	0.67
	N	65	65	65	65	65
Sex	r-value	-0.07	-0.05	0.02	0.05	0.42
	Sig. (2-tailed)	0.59	0.72	0.88	0.69	0.00
	N	65	65	65	65	65

A Spearman's correlation test was performed in order to determine the monotonic relationship between the independent and dependent variable. A Spearman's ρ value of greater than 0.75 was considered a high correlation, while a value between 0.5 and 0.74 was considered a moderate relationship, and finally a value less than 0.5 was considered a weak correlation. The results of the Spearman's correlation test are shown in Table 16 below. As can be seen, there is a weak negative correlation between the thickness of the genu (TG) ($\rho=-0.09$), thickness of the splenium (TS) ($\rho=-0.03$) with age. There was a weak positive correlation with the width of the trunk (TT) ($\rho=0.08$), length of the CC (LC) ($\rho=0.08$) and the length of the cerebrum (LB) ($\rho=-0.43$) with age. As can be seen there is a weak negative correlation between the thickness of the genu (TG) ($\rho=-0.09$), thickness of the splenium (TS) ($\rho=-0.03$), thickness of the trunk (TT) ($\rho=-0.15$), length of the CC (LC) ($\rho=-0.01$) and the length of the cerebrum (LB) ($\rho=-0.02$) with age. However, all these values are less than 0.5 and thus, are considered weak correlations.

Table 16. Spearman's correlation of the cadaver sample

		TG	TS	TT	LC	LB
Age	Spearman's ρ	-0.09	-0.03	0.08	0.08	0.43
	Sig. (2-tailed)	0.47	0.82	0.52	0.53	0.00
	N	65	65	65	65	65
Sex	Spearman's ρ	-0.23	-0.32	-0.15	-0.01	-0.02
	Sig. (2-tailed)	0.07	0.01	0.23	0.91	0.90
	N	65	65	65	65	65

The presence or absence of an isthmus was noted and recorded. An isthmus was found in 25% of the cadaver sample. There were 28 cases with a bulbous splenium and 17 of these were in the female cadaver population. The results are shown in Table 17 below.

Table 17. Table showing frequency of isthmus and bulbous splenium

	Number	Total percentage	Males vs Females
Isthmus	18	25%	Males: 9 Females: 9
Bulbous splenium	28	38.9%	Males: 11 Females: 17

4.2 Imaging study – healthy

Figure 25 shows the sex distribution of the healthy imaging sample. Measurements were taken on 127 healthy MRI scans, 76 females and 51 males.

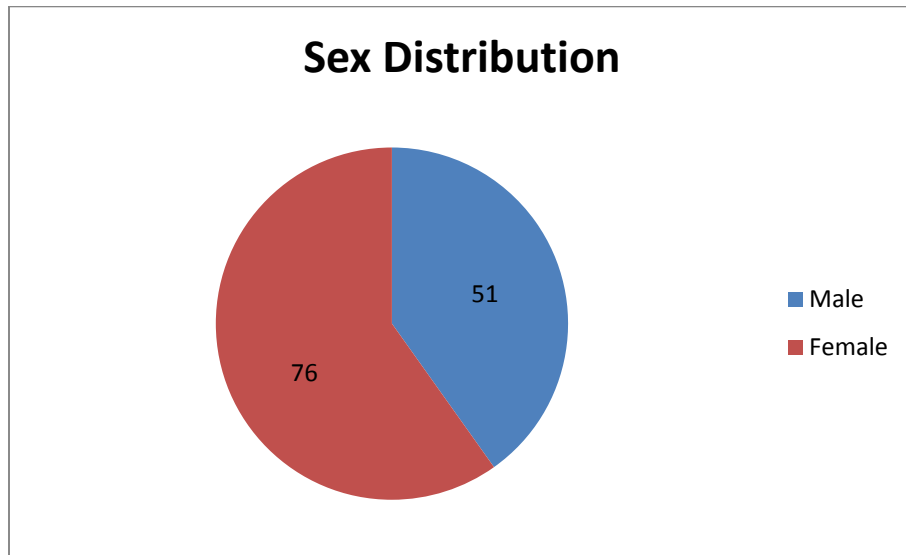


Figure 25. Sex distribution of the MRI scan sample

Figure 26 below shows the age distribution among the female scans of the MRI sample. As shown in Table 15 below, the maximum age was 83 years and the minimum age was 20 years. The mean age for the female MRI was 44.71 ± 15.93 years.

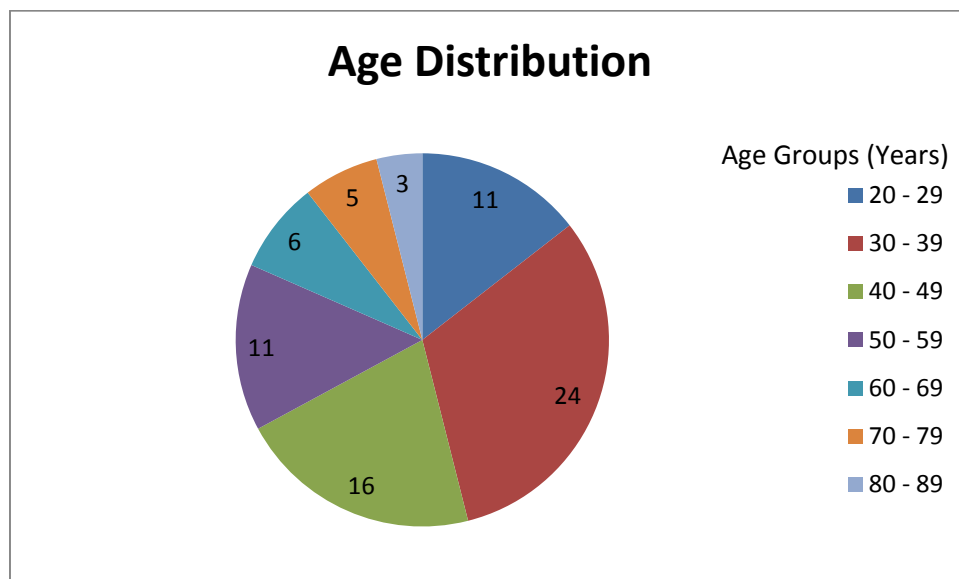


Figure 26. Age distribution of female MRI scan sample

Figure 27 shows the age distribution among the male scans of the MRI sample. As seen in Table 16 below, the maximum age was 78 years and the minimum age was 20 years. The mean age for the male MRI scan was 45.16 ± 14.89 years.

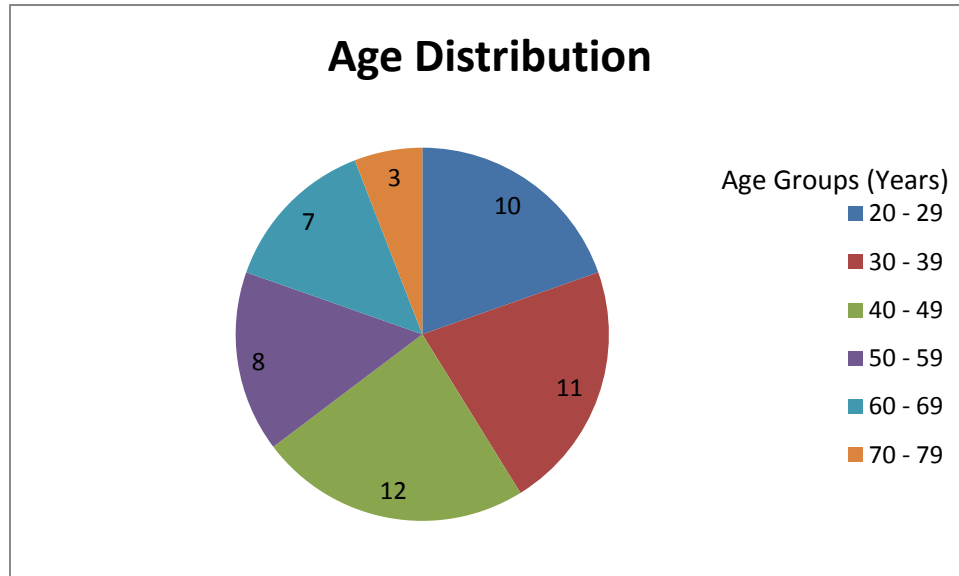


Figure 27. Age distribution of male MRI scan sample

Table 18 shows the descriptive statistics for specific parameters of the CC in female scans of the healthy MRI sample. Measurements were the thickness of the genu (TG), the vertical thickness of the splenium (TS), the thickness of the corpus or trunk (TS), the length of the CC (LC) and the length of the cerebrum (LB). As can be seen the mean ratio of the length of the CC to the length of the cerebrum is 2.17 ± 0.14 .

Table 18. Descriptive statistics of female MRI scans sample

	N	Minimum (mm)	Maximum (mm)	Mean (mm)	SD (mm)
Age	76	20	83	44.71	15.93
TG	76	4.70	13.70	10.37	1.70
TS	76	10.70	20.90	16.08	2.29
TT	76	2.90	7.60	5.51	0.95
LC	76	59.40	81.50	72.79	4.96
LB	76	134.30	172.60	157.07	7.22
Ratio	76	1.90	2.60	2.17	0.14

Table 19 shows the descriptive statistics for specific parameters of the CC in male scans of the healthy MRI sample. Measurements were the thickness of the genu (TG), the vertical thickness of the splenium (TS), the thickness of the corpus or trunk (TS), the length of the CC (LC) and the length of the cerebrum (LB). As can be seen the mean ratio of the length of the CC to the length of the cerebrum is 2.16 ± 0.16 .

Table 19. Descriptive statistics of male MRI scan sample

	N	Minimum (mm)	Maximum (mm)	Mean (mm)	SD (mm)
Age	51	20	78	45.16	14.89
TG	51	6.30	15.20	10.65	1.83
TS	51	11.90	22.40	16.79	2.33
TT	51	3.70	7.30	5.50	0.81
LC	51	63.10	94.80	75.01	6.77
LB	51	140.30	183.70	160.98	10.06
Ratio	51	1.70	2.60	2.16	0.16

Figure 28 shows a comparison between the mean measurements for the parameters measured between the sexes.

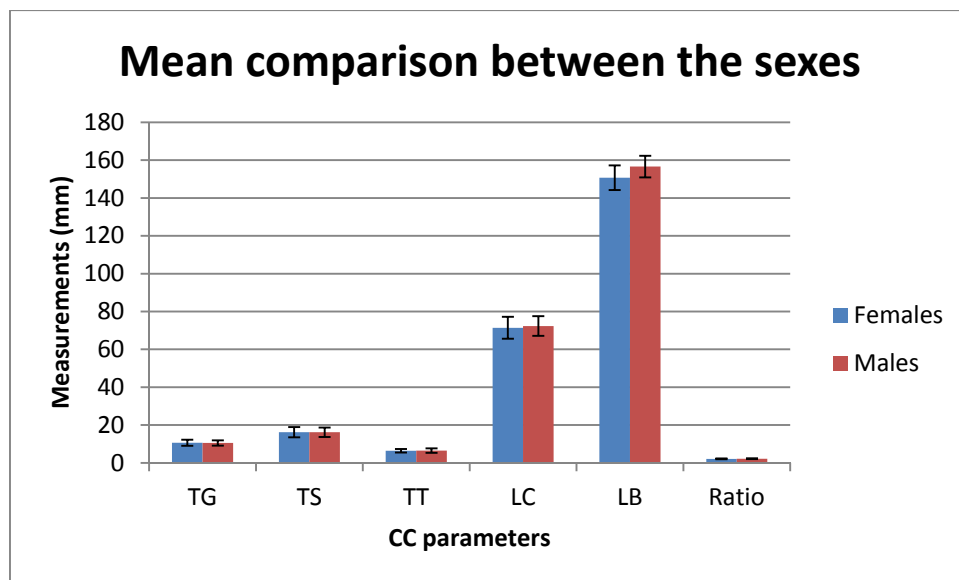


Figure 28. Mean comparison of CC parameters between the sexes in the MRI scan sample

Table 20 below shows the mean and standard deviation of the various CC parameters measured amongst the various age groups for the female MRI scans sample. Due to the fact that in some of the age groups there were less individuals, the age groups were joined together in order to have a more accurate group comparison. In the female healthy MRI scan sample individuals whose ages were between 18 to 39 years were grouped together in the 18 - 39 category (n=35). Individuals whose ages were between 40 to 59 years were grouped together in the 40 - 59 category (n=27). Individuals whose ages were between 60 to 99 years were grouped together in the 60 – 99 category (n=14). Table 17 below demonstrates the mean and standard deviation of the CC measurements amongst the various age groups described above in the female healthy MRI scan sample.

Table 20. Descriptive statistics of various age groups for female MRI scan sample

Age Group (years)		TG (mm)	TS (mm)	TT (mm)	LC (mm)	LB (mm)
18 - 39	Mean	10.78	15.97	5.72	71.06	157.35
	SD	1.70	2.39	1.04	4.75	5.83
40 - 59	Mean	10.19	16.45	5.42	75.03	158.13
	SD	1.75	2.01	0.90	5.02	7.47
80 -99	Mean	9.71	15.61	5.17	72.78	154.32
	SD	1.40	2.60	0.72	3.78	9.45

Table 21 below shows the mean and standard deviation of the various CC parameters measured amongst the various age groups for the male MRI scans sample. Due to the fact that in some of the age groups there were less individuals, the age groups were joined together in order to have a more accurate group comparison. In the male healthy MRI scan sample individuals whose ages were between 18 to 39 years were grouped together in the 18 - 39 category (n=21). Individuals whose ages were between 40 to 59 years were grouped together in the 40 - 59 category (n=20). Individuals whose ages were between 60 to 99 years were grouped together in the 60 – 99 category (n=10). Table 18 below demonstrates the mean and standard deviation of the CC measurements amongst the various age groups described above in the male cadaver sample.

Table 21. Descriptive statistics of various age groups for male MRI scan sample

Age Group (years)		TG (mm)	TS (mm)	TT (mm)	LC (mm)	LB (mm)
18 - 39	Mean	10.91	16.19	5.58	75.17	165.55
	SD	1.66	2.48	0.69	6.46	11.00
40 - 59	Mean	10.64	17.18	5.56	74.20	157.88
	SD	1.85	1.74	1.01	6.90	7.99
80 -99	Mean	10.14	17.28	5.23	76.01	157.56
	SD	2.21	2.95	0.55	7.63	8.71

An independent t-test was performed on the female and male samples in order to determine whether there was a significant difference between the parameters measured in the two sexes. The results are shown in Table 22 below. Levene's test for equality of variances was performed in order to determine the homogeneity of the standard deviation between the sexes. A p-value >0.05 was recorded for the measurements of the genu (TG) ($p=0.65$), splenium (TS) ($p=0.73$) and the corpus (TT) ($p=0.17$). Thus, the equality of variances can be assumed for those parameters for the male and female MRI sample. However, there was a significant difference ($p<0.05$) for the variances for the length of the CC (LC) ($p=0.02$) and the length of the cerebrum (LB) ($p=0.02$). Thus, equality of variances cannot be assumed for these two parameters.

Table 22. Mean comparisons between sexes of the MRI scan sample

		Levene's test for equality of variances		t-test for Equality of Means		
		F	Sig.	t	df	Sig. (2-tailed)
TG	Equal variances assumed	0.21	0.65	-0.88	125	0.38
	Equal variances not assumed			-0.87	101.78	0.39
TS	Equal variances assumed	0.12	0.73	-1.70	125	0.09
	Equal variances not assumed			-1.69	105.99	0.09
TT	Equal variances assumed	2.44	0.12	0.07	125	0.95
	Equal variances not assumed			0.07	118.36	0.95
LC	Equal variances assumed	5.88	0.02	-2.13	125	0.04
	Equal variances not assumed			-2.01	85.16	0.05
LB	Equal variances assumed	6.00	0.02	-2.54	125	0.01
	Equal variances not assumed			-2.39	83.82	0.02

There is no significant difference ($p > 0.05$) for the thickness of the genu (TG) ($p = 0.38$), and thickness of the trunk (TT) ($p = 0.95$). The thickness of the splenium (TS) ($p = 0.09$) is just above the significance level and thus is assumed to not be significantly different. However, there is a significant difference between the length of the CC (LC) ($p = 0.04$) and length of the cerebrum ($p = 0.01$).

A MANOVA test was performed in order to determine if there was a significant difference between the parameters measured for the different age groups. Table 23 below shows the differences between the groups. There was no significant difference ($p>0.05$) for the thickness of the genu (TG) ($p=0.08$), thickness of the splenium (TS) ($p=0.31$), thickness of the trunk (TT) ($p=0.09$), length of the CC (LC) ($p=0.17$) and the length of the cerebrum (LB) ($p=0.65$).

Table 23. Mean comparisons amongst various age groups of the MRI scan sample

	Dependent Variable	df	F	Sig.
Age Groups	TG	4	2.60	0.08
	TS	4	1.20	0.31
	TT	4	2.43	0.09
	LC	4	1.78	0.17
	LB	4	2.80	0.65

There was no need for a Scheffe's test to be performed as there were no significant differences observed among the various parameters.

A Pearson's correlation test was then performed in order to determine if there was a relationship between the dependent variable (age of the cadaver) and the independent variables (collected measurements of the various parameters). The results from the Pearson's correlation are shown in Table 24 below. As can be seen there is a weak negative correlation for the thickness of the genu (TG) ($r=-0.20$), thickness of the trunk (TT) ($r=-0.19$) and length of the cerebrum (LB) ($r=-0.21$) with age. There is a weak positive correlation with the thickness of the splenium (TS) ($r=0.08$) and the length of the CC (LC) ($r=0.13$) and age. As can be seen there is a weak negative correlation for thickness of the trunk (TT) ($r=-0.01$) with sex. There is a weak positive correlation with the thickness of the genu (TG) ($r=0.08$), the thickness of the splenium (TS) ($p=0.15$), the length of the CC (LC) ($r=0.19$) and length of the cerebrum (LB) ($r=0.22$) with sex. However, all these correlations are all under 0.5 and thus are considered weak correlations.

Table 24. Pearson's correlation of the MRI scan sample

		TG	TS	TT	LC	LB
Age	r-value	-0.20	0.08	-0.19	0.13	-0.21
	Sig. (2-tailed)	0.02	0.39	0.03	0.14	0.02
	N	127	127	127	127	127
Sex	r-value	0.08	0.15	-0.01	0.19	0.22
	Sig. (2-tailed)	0.38	0.09	0.94	0.04	0.01
	N	127	127	127	127	127

A Spearman's correlation test was performed in order to determine the monotonic relationship between the independent and dependent variables. A Spearman's ρ value of greater than 0.75 was considered a high correlation, while a value between 0.5 and 0.74 was considered a moderate relationship, and finally a value less than 0.5 was considered a weak correlation. The results of the Spearman's correlation test are shown in Table 25 below. As can be seen there is a weak negative correlation between the thickness of the genu (TG) ($\rho=-0.20$), the thickness of the trunk (TT) ($\rho=-0.20$) and the length of the cerebrum (LB) ($\rho=-0.16$) with age. There is a weak positive correlation between the thickness of the splenium (TS) ($\rho=0.08$) and the length of the CC (LC) ($\rho=0.13$) with age. As can be seen there is a weak negative correlation between the thickness of the trunk (TT) ($\rho=-0.02$) with sex. There is a weak positive correlation between the thickness of the genu (TG) ($\rho=-0.40$), the thickness of the splenium (TS) ($\rho=0.14$), the length of the CC (LC) ($\rho=0.14$) and the length of the cerebrum (LB) ($\rho=0.21$) with sex. However, all these values are below 0.5 and thus, are considered weak correlations.

Table 25. Spearman's correlation of the MRI scan sample

		TG	TS	TT	LC	LB
Age	Spearman's ρ	-0.20	0.08	-0.20	0.13	-0.16
	Sig. (2-tailed)	0.64	0.39	0.02	0.14	0.07
	N	127	127	127	127	127
Sex	Spearman's ρ	0.40	0.14	-0.02	0.14	0.21
	Sig. (2-tailed)	0.65	0.11	0.81	0.11	0.02
	N	127	127	127	127	127

The presence or absence of an isthmus was noted and recorded. It was found that in the overall MRI scan sample, 25.2% had an isthmus. There were 49 cases of a bulbous splenium that were recorded, and 30 of those cases were in the female healthy MRI scan sample. The results are shown in Table 26 below.

Table 26. Table showing frequency of isthmus and bulbous splenium

	Number	Total percentage	Males vs Females
Isthmus	32	25.2%	Males: 15 Females : 17
Bulbous splenium	49	38.5%	Males: 19 Females 30

4.3 Imaging study – mental disorders

Figure 29 shows the sex distribution of the mental disorder imaging sample. Measurements were taken on 63 mental disorder CT scans, 21 females and 42 males.

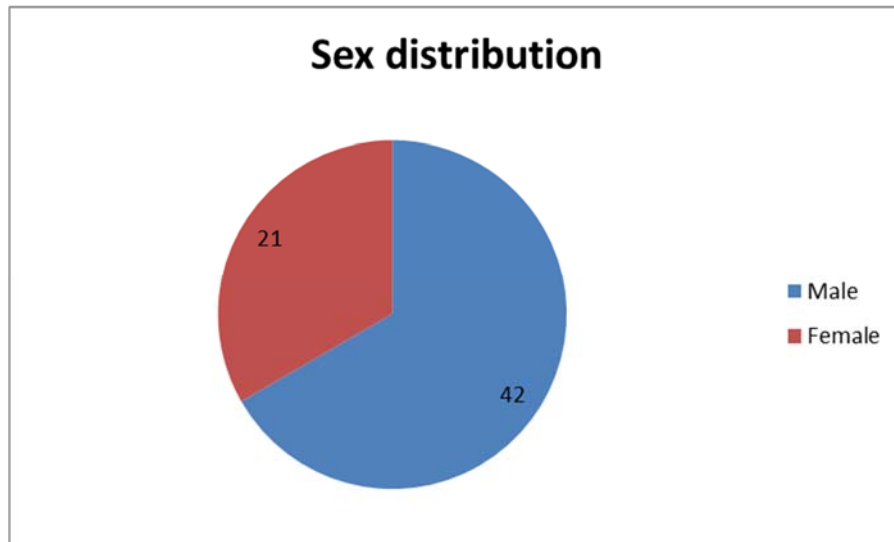


Figure 29. Sex distribution of mental disorder CT scan sample

Figure 30 below shows the age distribution among the CT scans of the mental disorder sample for the females. There was one individual whose age was unknown, that individual was used in the sex comparison but not in the comparison between the age groups. As shown in Table 24 below, the maximum age for the female CT scans (n=21) was 69 years and the minimum age was 19 years. The mean age for the female CT scans was 38.95 ± 15.15 years.

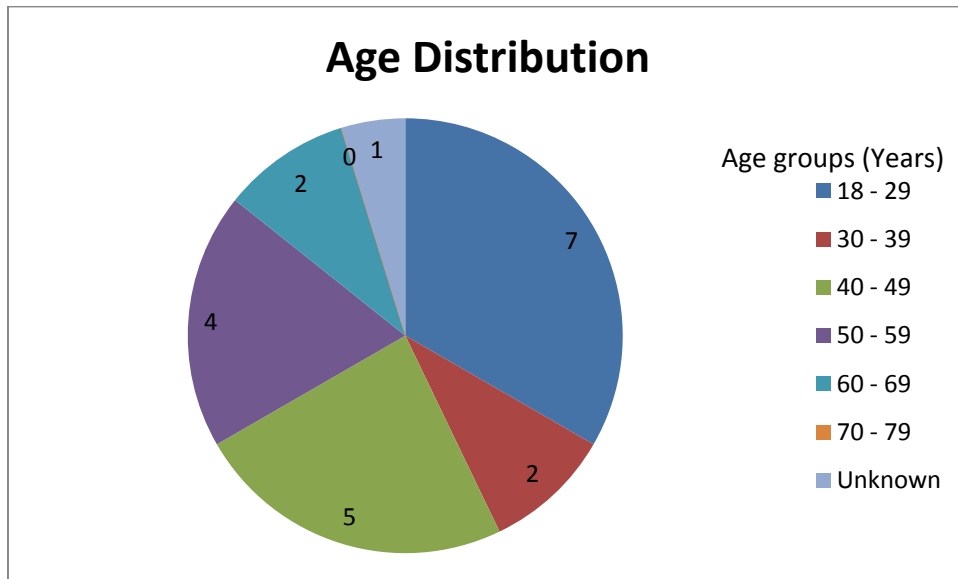


Figure 30. Age distribution of female mental disorder CT scan sample

Figure 31 below shows the age distribution among the CT scans of the mental disorder sample for the males. There were three individuals whose ages were unknown, thus, they were included in the sex comparison but not in the age comparison. As shown in Table 25 below, the maximum age for the male CT scans (n=42) was 83 years and the minimum age was 20 years. The mean age for the male CT scans was 44.71 ± 15.93 years.

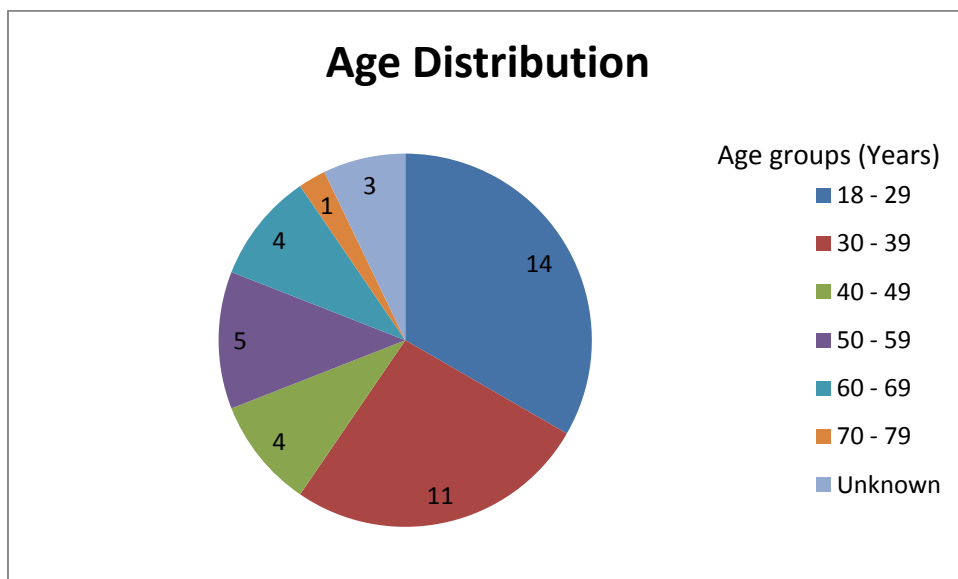


Figure 31. Age distribution of male mental disorder CT scan sample

Figure 32 below shows the distribution of the psychiatric disorders in the CT scan population. At the time of the scans, some of the patients did not have official diagnosis of mental disorders. They presented with symptoms of mental disorders. These patients were still included in this study.

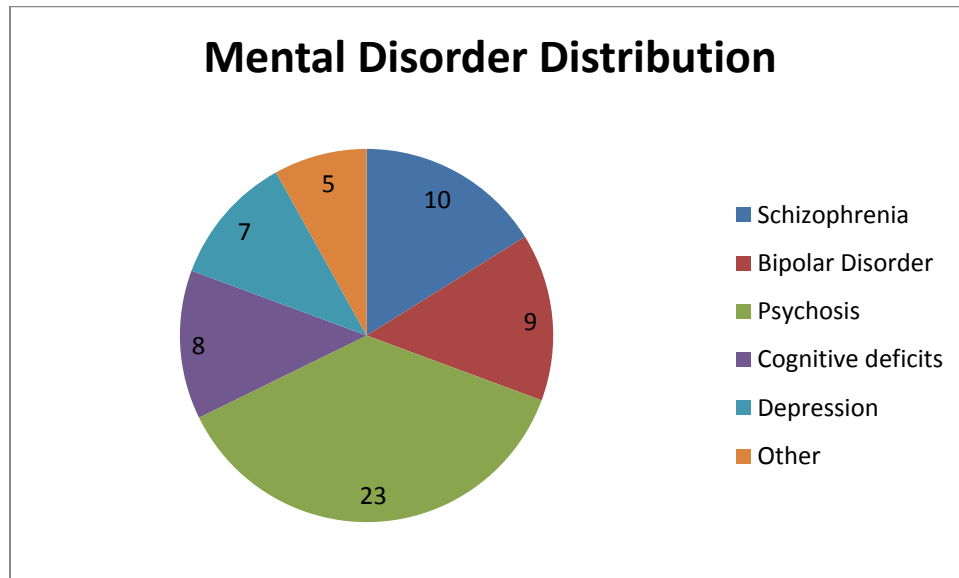


Figure 32. Mental disorder distribution for CT scan sample

Table 27 below shows the mean and standard deviation of the various CC parameters measured amongst the various age groups for the female CT scans sample. Measurements were the thickness of the genu (TG), the vertical thickness of the splenium (TS), the thickness of the corpus or trunk (TT), the length of the CC (LC) and the length of the cerebrum (LB). A ratio of length of CC (LC) to the length of the cerebrum (LB) was also calculated in order to demonstrate if the size of the CC was affected by the size of the brain. The ratio was 2.18 ± 0.19 in the female CT scan sample.

Table 27. Descriptive statistics of female CT scan sample

	N	Minimum (mm)	Maximum (mm)	Mean (mm)	SD (mm)
Age	21	19	69	38.95	15.15
TG	21	5.10	16.80	9.58	2.41
TS	21	12.80	22.50	17.47	2.78
TT	21	4.20	9.20	6.84	1.22
LC	21	65.30	93.10	74.96	7.36
LB	21	144.70	176.70	162.84	8.87
Ratio	21	1.80	2.50	2.18	0.19

Table 28 below shows the mean and standard deviation of the various CC parameters measured amongst the various age groups for the male CT scans sample. Measurements were the thickness of the genu (TG), the vertical thickness of the splenium (TS), the thickness of the corpus or trunk (TT), the length of the CC (LC) and the length of the cerebrum (LB). A ratio of length of CC (LC) to the length of the cerebrum (LB) was also calculated in order to demonstrate if the size of the CC was affected by the size of the brain. The ratio was 2.19 ± 0.17 in the male CT scan sample, which is almost exactly the same as that found in females.

Table 28. Descriptive statistics of male CT scan sample

	N	Minimum (mm)	Maximum (mm)	Mean (mm)	SD (mm)
Age	42	18	71	38.54	15.22
TG	42	6.50	15.20	9.62	2.26
TS	42	11.90	27.50	18.92	3.73
TT	42	3.90	9.40	6.42	1.16
LC	42	62.20	92.00	76.16	6.74
LB	42	143.70	186.40	167.02	10.43
Ratio	42	1.90	2.60	2.19	0.17

Figure 33 shows a comparison between the mean measurements for the parameters measured between the sexes.

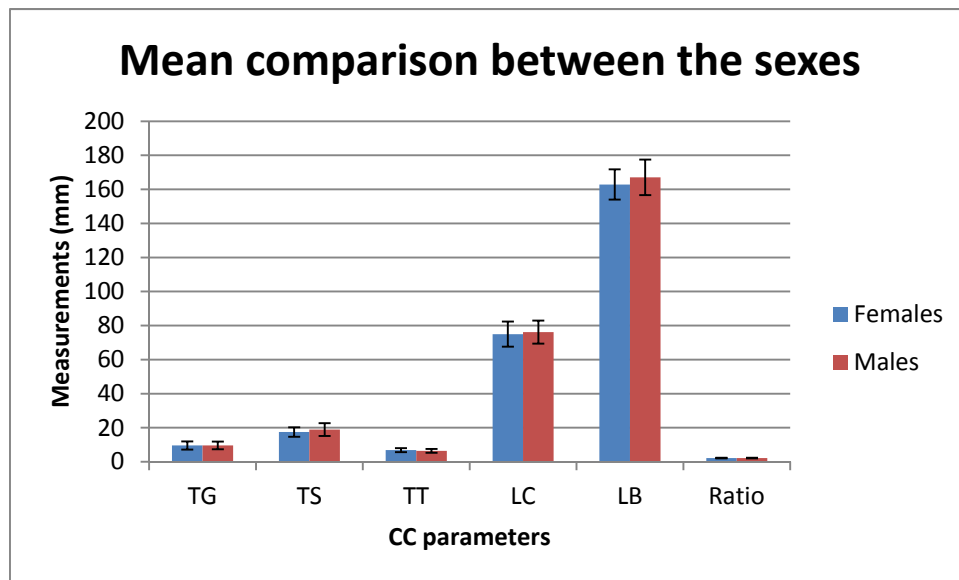


Figure 33. Mean comparison of CC parameters between the sexes in mental disorder CT scan sample

Table 29 below shows the mean and standard deviation of the various CC parameters measured amongst the various age groups for the female CT scan sample. Due to the fact that in some of the age groups there were less individuals, the age groups were joined together in order to have a more accurate group comparison. In the female mental disorder CT scan sample individuals whose ages were between 18 to 39 years were grouped together in the 18 - 39 category (n=9). Individuals whose ages were between 40 to 59 years were grouped together in the 40 - 59 category (n=9). Individuals whose ages were between 60 to 99 years were

grouped together in the 60 – 99 category (n=1). There was only one individual in the 60 – 99 age group, thus, there is no standard deviation for that group Table 26 below demonstrates the mean and standard deviation of the CC measurements amongst the various age groups described above in the female mental disorder CT scan sample.

Table 29. Descriptive statistics of various age groups for female CT scan sample

Age Group (years)		TG (mm)	TS (mm)	TT (mm)	LC (mm)	LB (mm)
18 - 39	Mean	10.60	16.00	6.87	75.78	169.19
	SD	2.64	2.84	1.06	7.26	4.00
40 - 59	Mean	8.59	18.62	6.89	75.33	160.86
	SD	2.21	2.58	1.17	8.11	6.95
80 -99	Mean	10.40	19.10	8.50	79.00	159.70
	SD					

Table 30 below shows the mean and standard deviation of the various CC parameters measured amongst the various age groups for the male CT scan sample. Due to the fact that in some of the age groups there were less individuals, the age groups were joined together in order to have a more accurate group comparison. In the male mental disorder CT scan sample individuals whose ages were between 18 to 39 years were grouped together in the 18 - 39 category (n=25). Individuals whose ages were between 40 to 59 years were grouped together in the 40 - 59 category (n=9). Individuals whose ages were between 60 to 99 years were grouped together in the 60 – 99 category (n=5). Table 8 below demonstrates the mean and standard deviation of the CC measurements amongst the various age groups described above in the male cadaver sample.

Table 30. Descriptive statistics of various age groups for male CT scan sample

Age Group (years)		TG (mm)	TS (mm)	TT (mm)	LC (mm)	LB (mm)
18 - 39	Mean	9.53	18.04	6.51	75.22	167.24
	SD	2.36	4.15	1.09	7.01	10.51
40 - 59	Mean	8.94	20.30	6.88	75.10	163.41
	SD	1.96	2.69	1.32	6.57	7.21
80 -99	Mean	10.04	19.26	5.82	79.78	172.28
	SD	2.16	2.62	1.03	4.76	13.29

Table 31 below shows the mean and standard deviation of the various CC parameters measured amongst the various mental disorders observed in the CT scan sample.

Table 31. Descriptive statistics for the various mental disorders

Disorder		TG (mm)	TS (mm)	TT (mm)	LC (mm)	LB (mm)	Ratio (mm)
Schizophrenia	Mean	10.52	18.81	6.32	75.93	171.28	2.27
	SD	2.62	4.18	1.15	8.82	6.63	0.23
	Min	7.10	12.80	3.90	65.10	163.20	1.90
	Max	15.20	24.70	7.60	90.30	186.10	2.60
Bipolar disorder	Mean	8.60	18.60	6.50	73.47	161.20	2.20
	SD	2.08	3.81	0.93	5.98	8.17	0.14
	Min	6.50	12.90	5.20	62.20	151.50	2.00
	Max	12.30	27.50	8.20	85.60	175.00	2.50
Psychosis	Mean	9.62	17.66	6.68	77.43	167.06	2.16
	SD	2.43	3.69	1.20	7.52	10.12	0.19
	Min	7.00	11.90	4.60	64.50	143.70	1.80
	Max	16.80	27.50	9.40	93.10	186.40	2.40
Cognitive deficits	Mean	9.70	18.48	6.51	74.45	162.06	2.16
	SD	2.28	2.80	1.21	3.68	8.37	0.07
	Min	5.30	14.90	4.60	68.60	144.70	2.10
	Max	13.30	21.90	8.30	78.50	169.20	2.30
Depression	Mean	9.03	18.17	7.07	73.15	168.93	2.30
	SD	2.20	2.99	1.45	7.81	12.08	0.09
	Min	5.10	14.40	5.10	65.30	157.90	2.20
	Max	11.90	21.90	9.20	85.80	185.50	2.40
Other	Mean	9.48	20.08	7.48	76.70	162.28	2.10
	SD	1.10	3.04	0.71	2.31	10.72	0.20
	Min	7.90	17.30	6.90	73.50	153.20	2.00
	Max	10.40	24.40	8.50	79.00	177.80	2.40

An independent t-test was performed on the female and male sexes in order to determine whether there was a significant difference between the parameters measured in the two sexes. The results are shown in Table 32 below. Levene's test for equality of variances was performed in order to determine the homogeneity of the standard deviation between the sexes. A p-value >0.05 was recorded for the measurements of the genu (TG) (p=0.62), splenium (TS) (p=0.26) and the corpus (TT) (p=0.85), length of the CC (LC) (p=0.61) and the length of the cerebrum (LB) (p=0.67). Thus, equality of variances can be assumed for these parameters.

Table 32. Mean comparison between the sexes for CT scan sample

		Levene's Test for Equality of Variances		t-test for Equality of Means		
		F	Sig.	t	df	Sig. (2-tailed)
TG	Equal variances assumed	0.24	0.62	-0.06	61	0.95
	Equal variances not assumed			-0.06	37.9	0.95
TS	Equal variances assumed	1.30	0.26	-1.57	61	0.12
	Equal variances not assumed			-1.73	51.7	0.09
TT	Equal variances assumed	0.34	0.85	1.34	61	0.19
	Equal variances not assumed			1.31	38.3	0.20
LC	Equal variances assumed	0.26	0.61	-0.65	61	0.52
	Equal variances not assumed			-0.63	57.1	0.53
LB	Equal variances assumed	0.19	0.67	-1.57	61	0.12
	Equal variances not assumed			-1.66	46.4	0.10

There is no significant difference ($p>0.05$) for the thickness of the genu (TG) ($p=0.95$), the thickness of the splenium (TS) ($p=0.12$), thickness of the trunk (TT) ($p=0.19$), length of the CC (LC) ($p=0.52$) and length of the cerebrum ($p=0.12$) between the mental disorders.

A MANOVA test was performed in order to determine if there was a significant difference between the parameters measured for the different age groups. Table 33 below shows the differences between the groups. There was no significant difference ($p>0.05$) for the thickness of the genu (TG) ($p=0.23$), thickness of the splenium (TS) ($p=0.13$), thickness of the trunk (TT) ($p=0.58$), length of the CC (LC) ($p=0.61$) and the length of the cerebrum (LB) ($p=0.13$).

Table 33. Mean comparison amongst various age groups for the CT scan sample

	Dependent Variable	df	F	Sig.
Age Groups	TG	4	0.90	0.23
	TS	4	1.19	0.13
	TT	4	0.55	0.58
	LC	4	0.79	0.61
	LB	4	1.46	0.13

There was no need for a Scheffe's test to be performed as there were no significant differences observed among the various parameters between the different age groups.

A MANOVA test was performed in order to determine if there was a significant difference between the parameters measured for the different mental disorders. Table 34 below shows the differences between the groups. There was no significant difference ($p>0.05$) for the thickness of the genu (TG) ($p=0.65$), thickness of the splenium (TS) ($p=0.56$), thickness of the trunk (TT) ($p=0.87$), length of the CC (LC) ($p=0.67$) and the length of the cerebrum (LB) ($p=0.27$).

Table 34. Mean comparison of various mental disorders for CT scan sample

	Dependent Variable	df	F	Sig.
Mental disorders	TG	5	0.67	0.65
	TS	5	0.79	0.56
	TT	5	0.36	0.87
	LC	5	0.64	0.67
	LB	5	1.32	0.27

There was no need for a Scheffe's test to be performed as there were no significant differences observed among the various parameters measured between the different mental disorders.

A Pearson's correlation test was then performed in order to determine if there was a relationship between the dependent variable (age and sex) and the independent variables (collected measurements of the various parameters). The results from the Pearson's correlation are shown in Table 35 below. As can be seen there is a weak negative correlation for the thickness of the genu (TG) ($r=-0.11$) and length of the cerebrum (LB) ($r=-0.16$) with age. There is a weak positive correlation with the thickness of the splenium (TS) ($r=0.26$), thickness of the trunk (TT) ($r=0.04$) and the length of the CC (LC) ($r=0.06$) and age. There is a weak negative correlation for the thickness of the trunk (TT) ($r=0.12$). There is a weak positive correlation of the genu (TG) ($r=-0.11$) and length of the cerebrum (LB) ($r=-0.16$) with age. There is a weak positive correlation with the thickness of the splenium (TS) ($r=0.26$), thickness of the trunk (TT) ($r=0.04$) and the length of the CC (LC) ($r=0.06$) and sex. However, all these correlations are all under 0.5 and thus are considered weak correlations.

Table 35. Pearson's correlation of CT scan sample

		TG	TS	TT	LC	LB
Age	r-value	-0.06	0.23	0.00	0.09	-0.15
	Sig. (2-tailed)	0.64	0.07	0.98	0.48	0.26
	N	59	59	59	59	59
Sex	r-value	-0.04	0.17	-0.20	0.03	0.16
	Sig. (2-tailed)	0.76	0.19	0.14	0.84	0.22
	N	59	59	59	59	59

A Spearman's correlation test was performed in order to determine the monotonic relationship between the independent and dependent variable. A Spearman's ρ value of greater than 0.75 was considered a high correlation, while a value between 0.5 and 0.74 was considered a moderate relationship, and finally a value less than 0.5 was considered a weak correlation. The results of the Spearman's correlation test are shown in Table 36 below. As can be seen there is a weak negative correlation between the length of the cerebrum ($\rho=-0.21$) with age. There is a weak positive correlation with the thickness of the genu (TG) ($\rho=0.00$), the thickness of the splenium (TS) ($\rho=0.32$), the thickness of the trunk (TT) ($\rho=0.04$) and the length of the CC (LC) ($\rho=0.06$) with age. However, all these values are below 0.5 and thus, are considered weak correlations. There is a weak negative correlation between the thickness of the genu (TG) ($\rho=-0.11$) and the thickness of the trunk ($\rho=-0.20$) with sex. There is a weak positive correlation with the thickness of the splenium (TS) ($\rho=0.16$), the length of the CC (LC) ($\rho=0.09$) and the length of the cerebrum (LB) ($\rho=0.15$) with sex. However, all these values are below 0.5 and thus, are considered weak correlations.

Table 36. Spearman's correlation of CT scan sample

		TG	TS	TT	LC	LB
Age	Spearman's ρ	0.03	0.32	0.04	0.06	-0.21
	Sig. (2-tailed)	0.98	0.01	0.75	0.64	0.26
	N	59	59	59	59	59
Sex	Spearman's ρ	-0.11	0.16	-0.20	0.09	0.15
	Sig. (2-tailed)	0.40	0.21	0.14	0.50	0.26
	N	59	59	59	59	59

The presence or absence of an isthmus was noted and recorded. It was found that in the overall MRI scan sample, 34.9% had an isthmus. There were 26 cases of a bulbous splenium that were recorded, and 9 of those cases were in the female mental disorder CT scan sample. The results are shown in Table 37 below.

Table 37. Table showing frequency of isthmus and bulbous splenium

	Number	Total percentage	Males vs Females
Isthmus	22	34.9%	Males: 16 Females : 6
Bulbous splenium	26	41.3%	Males: 17 Females 9

4.4 Comparison between the three samples

In order to address Research Objective 5, a MANOVA test was performed to determine whether a significant difference exists between the independent variables (sample set, sex and age groups) with the dependent variables (measurements of the various CC parameters). The mean and standard deviation results are shown in Table 38 below.

Table 38. Descriptive statistics of the three sample sets

	Sex	Type	Age Group	Mean (mm)	SD (mm)	N
TG	Female	Cadaver	18 - 39	11.16	1.85	5
			40 - 59	11.44	1.05	9
			60 - 99	9.90	1.57	15
		Healthy MRI	18 - 39	10.78	1.70	35
			40 - 59	10.19	1.75	27
			60 - 99	9.71	1.40	14
		Mental disorder CT	18 - 39	10.60	2.64	9
			40 - 59	8.59	2.21	9
			60 - 99	10.20	0.28	2
	Male	Cadaver	18 - 39	11.03	1.21	4
			40 - 59	10.38	1.06	4
			60 - 99	10.29	1.44	28
		Healthy MRI	18 - 39	10.91	1.66	21
			40 - 59	10.64	1.85	20
			60 - 99	10.14	2.21	10
		Mental disorder CT	18 - 39	9.53	2.36	25
			40 - 59	8.94	1.96	9
			60 - 99	10.04	2.16	5
TS	Female	Cadaver	18 - 39	14.88	1.85	5
			40 - 59	17.76	2.42	9
			60 - 99	15.49	2.47	15
		Healthy MRI	18 - 39	15.97	2.39	35
			40 - 59	16.45	2.01	27
			60 - 99	15.67	2.60	14
		Mental disorder CT	18 - 39	16.00	2.84	9
			40 - 59	18.62	2.58	9
			60 - 99	19.10	0.00	2
	Male	Cadaver	18 - 39	17.43	3.51	4
			40 - 59	17.33	1.31	4
			60 - 99	15.43	2.24	28
		Healthy MRI	18 - 39	16.19	2.48	21
			40 - 59	17.18	1.74	20
			60 - 99	17.28	2.95	10
		Mental disorder CT	18 - 39	18.08	4.15	25
			40 - 59	20.30	2.69	9
			60 - 99	19.26	2.62	5

	Sex	Type	Age Group	Mean (mm)	SD (mm)	N
TT	Female	Cadaver	18 - 39	6.22	0.69	5
			40 - 59	6.59	1.13	9
			60 - 99	6.22	0.97	15
		Healthy MRI	18 - 39	5.72	1.04	35
			40 - 59	5.42	0.90	27
			60 - 99	5.17	0.72	14
		Mental disorder CT	18 - 39	6.87	1.06	9
			40 - 59	6.89	1.17	9
			60 - 99	7.85	0.92	2
	Male	Cadaver	18 - 39	6.50	1.81	4
			40 - 59	6.78	0.88	4
			60 - 99	6.31	1.32	28
		Healthy MRI	18 - 39	5.58	0.69	21
			40 - 59	5.56	1.01	20
			60 - 99	5.23	0.55	10
		Mental disorder CT	18 - 39	6.51	1.09	25
			40 - 59	6.88	1.32	9
			60 - 99	5.82	1.03	5
LC	Female	Cadaver	18 - 39	71.48	4.32	5
			40 - 59	72.37	6.20	9
			60 - 99	70.87	6.41	15
		Healthy MRI	18 - 39	71.06	4.75	35
			40 - 59	75.03	5.02	27
			60 - 99	72.78	3.78	14
		Mental disorder CT	18 - 39	75.78	7.26	9
			40 - 59	75.33	8.11	9
			60 - 99	73.80	7.35	2
	Male	Cadaver	18 - 39	69.55	9.28	4
			40 - 59	71.78	4.96	4
			60 - 99	72.38	4.66	28
		Healthy MRI	18 - 39	75.17	6.46	21
			40 - 59	74.20	6.90	20
			60 - 99	76.31	7.63	10
		Mental disorder CT	18 - 39	75.22	7.01	25
			40 - 59	75.10	6.57	9
			60 - 99	79.78	4.76	5

	Sex	Type	Age Group	Mean (mm)	SD (mm)	N
LB	Female	Cadaver	18 - 39	152.06	3.80	5
			40 - 59	152.34	7.68	9
			60 - 99	148.91	6.48	15
		Healthy MRI	18 - 39	157.35	5.83	35
			40 - 59	158.13	7.47	27
			60 - 99	154.32	9.45	14
		Mental disorder CT	18 - 39	169.19	4.00	9
			40 - 59	160.86	6.95	9
			60 - 99	152.20	10.61	2
	Male	Cadaver	18 - 39	156.73	6.95	4
			40 - 59	153.72	5.19	4
			60 - 99	156.10	5.41	28
		Healthy MRI	18 - 39	165.55	11.00	21
			40 - 59	157.88	7.99	20
			60 - 99	157.56	8.71	10
		Mental disorder CT	18 - 39	167.24	10.51	25
			40 - 59	163.41	7.21	9
			60 - 99	172.28	13.29	5

The results of the MANOVA comparison for the overall sample are shown below in Table 39. The thickness of the genu (TG) ($p=0.81$), thickness of the trunk (TT) ($p=0.26$) and length of the CC (LC) ($p=0.23$) showed no statistically significant differences. However, there was a statistically significant difference between the sexes with regard to the thickness of the splenium (TS) ($p=0.03$) and the length of the cerebrum (LB) ($p=0.00$). With regard to the mean comparisons between the three sample sets, statistically significant differences were observed for all CC parameters measured. The thickness of the genu (TS) ($p=0.04$), thickness of the splenium (TS) ($p=0.00$), thickness of the trunk ($p=0.00$) and length of the CC (LC) ($p=0.01$) and the length of the cerebrum (LB) ($p=0.00$) all were below the significant level. With regards to the mean comparisons between the various age groups, there were statistically significant differences observed in some of the CC parameters. These were seen in the thickness of the splenium ($p=0.01$) and the length of the cerebrum ($p=0.01$). There was no statistically significant difference observed in the thickness of the genu (TG) ($p=0.13$), thickness of the trunk (TT) ($p=0.52$) and the length of the CC

(LC) ($p=0.57$). Thus, a Scheffe's test was performed in order to determine which of the groups differed.

Table 39. Mean comparison between the sample sets

	Dependent Variable	df	F	Sig.
Sex	TG	1	0.06	0.81
	TS	1	4.63	0.03
	TT	1	1.29	0.26
	LC	1	1.45	0.23
	LB	1	13.97	0.00
Sample Set	TG	2	3.22	0.04
	TS	2	9.07	0.00
	TT	2	28.58	0.00
	LC	2	5.21	0.01
	LB	2	17.12	0.00
Age Groups	TG	2	2.02	0.13
	TS	2	4.55	0.01
	TT	2	0.65	0.52
	LC	2	0.57	0.57
	LB	2	4.32	0.01

A Scheffe's comparison was then performed in order to determine which groups differed from one another; the results for the between all three samples are shown in Table 40 below. With regards to the thickness of the genu (TG), a significant difference was observed between the cadaver and the mental disorder CT sample ($p=0.02$), and between the healthy MRI and mental disorder CT sample ($p=0.00$). There was no difference observed between the cadaver and healthy MRI scan sample ($p=0.99$). With regards to the thickness of the splenium (TS), a significant difference was observed between the cadaver and the mental disorder CT sample ($p=0.00$), and between the healthy MRI and mental disorder CT sample ($p=0.00$). There was no difference observed between the cadaver and healthy MRI scan sample ($p=0.56$). With regards to the thickness of the trunk (TT), a statistically significant difference was observed between the cadaver and the healthy MRI sample ($p=0.00$), and between the healthy MRI and the mental disorder CT sample ($p=0.00$). With regards to the length of the CC (LC), a significant difference was

observed between the cadaver and the mental disorder CT sample ($p=0.00$). There was no difference observed between the cadaver and healthy MRI sample ($p=0.11$), and the healthy MRI scan sample and mental disorder CT sample ($p=0.12$). With regards to the length of the cerebrum (LB), a significant difference was observed between the cadaver and the healthy MRI scan ($p=0.00$), as well as with the mental disorder CT scan sample ($p=0.05$). There was a statistically significant difference observed between the healthy MRI and mental disorder CT sample ($p=0.00$).

Table 40. Scheffe's test between the sample sets

Dependent Variable	Sample set	Sample set	Sig.
TG	Cadaver	Healthy MRI	0.99
		Mental disorder CT	0.02
	Healthy MRI	Cadaver	0.99
		Mental disorder CT	0.00
TS	Cadaver	Healthy MRI	0.56
		Mental disorder CT	0.00
	Healthy MRI	Cadaver	0.56
		Mental disorder CT	0.00
TT	Cadaver	Healthy MRI	0.00
		Mental disorder CT	0.26
	Healthy MRI	Cadaver	0.00
		Mental disorder CT	0.00
LC	Cadaver	Healthy MRI	0.11
		Mental disorder CT	0.00
	Healthy MRI	Cadaver	0.11
		Mental disorder CT	0.12
LB	Cadaver	Healthy MRI	0.00
		Mental disorder CT	0.00
	Healthy MRI	Cadaver	0.00
		Mental disorder CT	0.00

A Scheffe's comparison was then performed in order to determine which groups differed from one another; the results for the between age groups are shown in Table 41 below. With regards to the thickness of the genu (TG), there was no statistically significant difference observed between the 18 – 39 and 40 – 59 age group ($p=0.40$),

the 18 – 39 and 60 – 99 age group ($p=0.28$), and the 40 – 59 and 60 – 99 age groups ($p=0.97$). With regards to the thickness of the splenium (TS), there was no statistically significant difference observed between the 18 – 39 and 40 – 59 age group ($p=0.05$), the 18 – 39 and 60 – 99 age group ($p=0.52$). There was a statistically significant difference observed the thickness of the splenium in the 40 – 59 and 60 – 99 age groups ($p=0.00$). With regards to the thickness of the trunk (TT), there was no statistically significant difference observed between the 18 – 39 and 40 – 59 age group ($p=0.94$), the 18 – 39 and 60 – 99 age group ($p=0.78$), and the 40 – 59 and 60 – 99 age groups ($p=0.94$). With regards to the length of the CC (LC), there was no statistically significant difference observed between the 18 – 39 and 40 – 59 age group ($p=0.54$), the 18 – 39 and 60 – 99 age group ($p=0.99$), and the 40 – 59 and 60 – 99 age groups ($p=0.49$).. With regards to the length of the cerebrum (LB), there was a statistically significant difference observed between the 18 – 39 and 40 – 59 age group ($p=0.00$), the 18 – 39 and 60 – 99 age group ($p=0.00$). There was no statistically significant difference observed in the 40 – 59 and 60 – 99 age group ($p=0.13$).

Table 41. Scheffe's test between the age groups

Dependent Variable	Sample set	Sample set	Sig.
TG	18 - 39	40 - 59	0.40
		60 - 99	0.28
	40 - 59	18 - 39	0.40
		60 - 99	0.97
TS	18 - 39	40 - 59	0.05
		60 - 99	0.52
	40 - 59	18 - 39	0.05
		60 - 99	0.00
TT	18 - 39	40 - 59	0.94
		60 - 99	0.78
	40 - 59	18 - 39	0.94
		60 - 99	0.94
LC	18 - 39	40 - 59	0.54
		60 - 99	0.99
	40 - 59	18 - 39	0.54
		60 - 99	0.49
LB	18 - 39	40 - 59	0.00
		60 - 99	0.00
	40 - 59	18 - 39	0.00
		60 - 99	0.13

5 Discussion

Current research topics that are looking to define morphometrics of anatomical structures make use of a variety of different data acquisition techniques (Broadfield, 2001). The technological advancement of the equipment used to quantify anatomical structures that are relatively non-invasive has allowed for the study of living samples from MRI and CT scans to be compared to the information gained from cadaver-only research (Broadfield, 2001, Schoeman, 2016). The data acquisition techniques employed in this study has sought to use advanced technologies in order to gain the most accurate results possible.

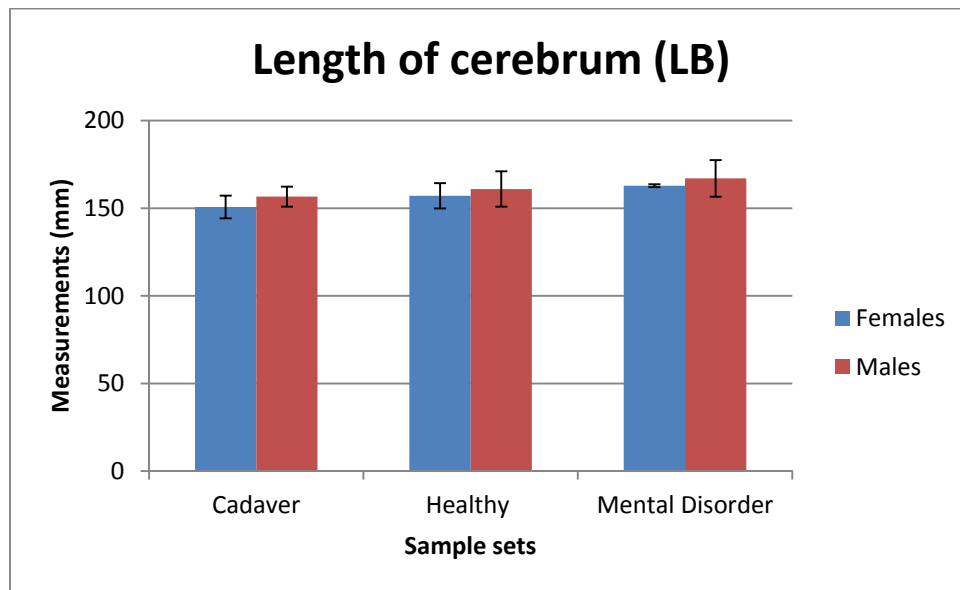
Thus, with that in mind, the researchers decided to use AutoCAD 2015 edition in order to measure the images as this technology has the ability to accurately measure photographic images with dense pixilation (Fiorentino *et al.*, 2004). This is important, especially for a study that focuses on minor variations in size that can have major impacts on morphology, function and composition (Broadfield, 2001). A limitation of morphological studies on the brain, when compared to those on bony elements, is that the results provide an indication of the functionality of the structure measured (Broadfield, 2001). In order to interpret these observed differences, the composition of the structure needs to be studied.

The focal length of a camera is a calculation of the optical distance from a point in space where light rays converge to form a sharp image of an object (Moran *et al.*, 2006). The focal length of a camera describes how large individual elements will be and how much of the scene will be captured. Thus, if the focal length becomes longer, the angle of view will become narrower and result in a higher magnification while if the angle widens, the magnification will decrease. In this study, the least amount of magnification was desired in order to capture real representations of the brains. Thus, a GoPro Hero 4 Black with a wide-angle lens was used in order to minimize the magnification and capture 'real life' images.

5.1 Sex differences in total midsagittal callosal length and length of the brain

The length of the cerebrum (LB) was measured in all sample populations, the mean values are shown in Table 42 below. In the cadaver sample, a statistically significant difference ($p=0.00$) was observed between the sexes with regards to the length of the cerebrum (LB). There was a statistically significant difference seen the length of the cerebrum in the healthy MRI sample ($p=0.04$). These results are in agreement with a study conducted by Gupta *et al.*, (2008) it was found that the length of the cerebrum was $152 \text{ mm} \pm 8.2$, while in the males it was $164.40 \text{ mm} \pm 10.8$, the p-value was <0.00 . There were no statistically significant differences seen in the length of the cerebrum (LB) between the sexes in the mental disorder sample ($p=0.12$). These results are consistent with a study conducted by Collison *et al.*, (2014), the p-value was <0.05 .

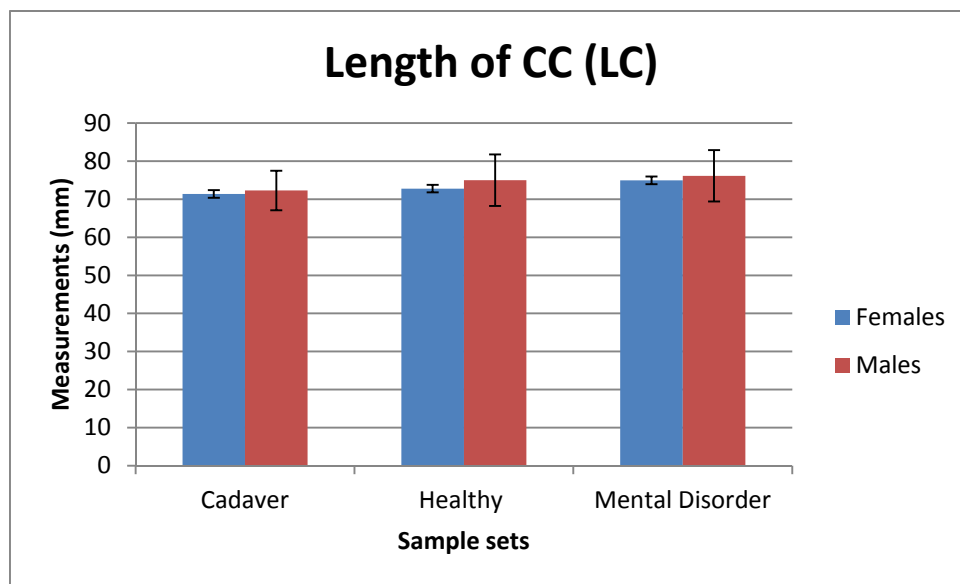
Table 42. Table showing length of cerebrum (LB)



The length of the CC (LC) was measured and the mean values are reported in Table 43 below. There was no statistically significant difference between the sexes in the cadaver sample ($p=0.69$). In the healthy MRI scan sample, there was a statistically significant difference observed with regard to the length of the CC ($p=0.02$). These results are in agreement with a study by Sungathy *et al.*, (2003) it was found that the length of the CC in females was $70.6 \pm 4.0 \text{ mm}$, while in the males it was $72.6 \pm 5.2 \text{ mm}$ ($p=0.03$). A significant difference was also observed in a study by Gupta *et al.*,

(2008). In which it was shown that the length of the CC in females was 71.1 ± 4.10 mm, while in the males it was 75.7 ± 6.2 mm ($p=0.03$). A possible reason for this difference is the different MRI resolutions used between this study and that of others. The orientation of the scans could also possibly introduce a slight difference in measurements. In the mental disorder sample, there was no statistically significant difference observed in the length of the CC ($p=0.52$).

Table 43. Table showing length of CC (LC)



Luders *et al.*, (2014) stated that individual differences in brain size were responsible for apparent sex differences. In order to address research objective three, a ratio of the length of the CC to the length of the brain was calculated. It was found that for both sexes the ratio was approximately 2. Thus, the length of the brain is approximately twice the length of the CC. It shows that the size difference between the sexes in brain length does not influence the measurements of the subregions of the CC. These results are in agreement with studies conducted by Luders *et al.*, (2014) in which it was demonstrated that any observed sex differences that were found were from size variation, and not from sex-related characteristics. This means that any sexual dimorphism observed is not due to the fact that males are physically larger than females, but rather suggest that the differences are due to function.

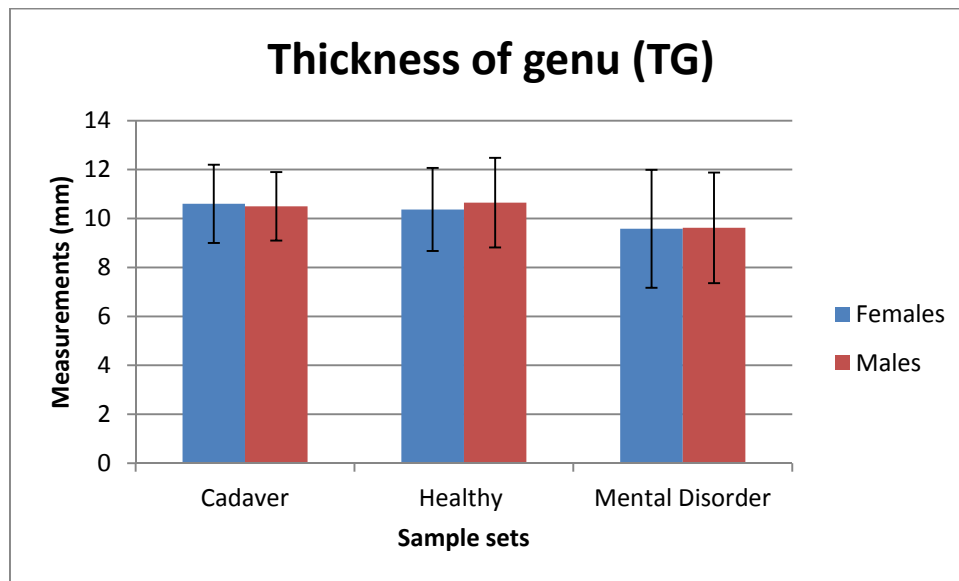
5.2 Sex differences in subregions of the CC

As discussed above, there was no difference observed in the samples between males and females with regard to overall length of the CC to the cerebrum. The CC is an exceptionally complex structure and thus further analysis of the various subregions with regard to possible sex differences needs to be made.

5.2.1 *Thickness of the genu (TG)*

The genu in this study was defined using the Witelson technique described in Section 2 above, which makes use of the straight line method (Witelson, 1989). Thus the measurements performed on the anterior one fifth of the CC will be referred to as the genu. The genu is an area of the CC that has been documented in literature to demonstrate sexual dimorphism in studies conducted by Dubb *et al.*, (2003) and Prendergrast *et al.*, (2015), which demonstrated that the genu was larger in males than females. The genu connects the prefrontal and motor cortex and the suggested reason for the larger genu is the increase in motor coordination observed in males (Broadfield, 2001, Ozdemir *et al.*, 2007). There was no statistically significant difference observed between the sexes in the cadaver sample ($p=0.59$), and the healthy MRI scan sample ($p=0.38$). These results are in agreement with a study conducted by Sungathy *et al.*, (2003) who found that the width of the genu was not statistically significant between the sexes ($p=0.81$). In a study by Ozdemir *et al.*, 2007 the authors found that, even though most of the differences that were greater in men were found in the genu, none of the differences were statistically significant between the two sexes. There was no statistically significant difference observed between the sexes in the mental disorder sample ($p=0.95$). This is in agreement with Collison *et al.*, (2014) in which it was observed that there was no statistically significance difference in the size of the genu. These were in contrast to a study conducted by Ellison-Wright *et al.*, (2014) who reported that there was a statistically significant reduction in the size of the genu in schizophrenic patients ($p<0.05$). The mean values of the thickness of the genu between the sample sets are shown in Table 44 below.

Table 44. Table showing thickness of genu (TG)



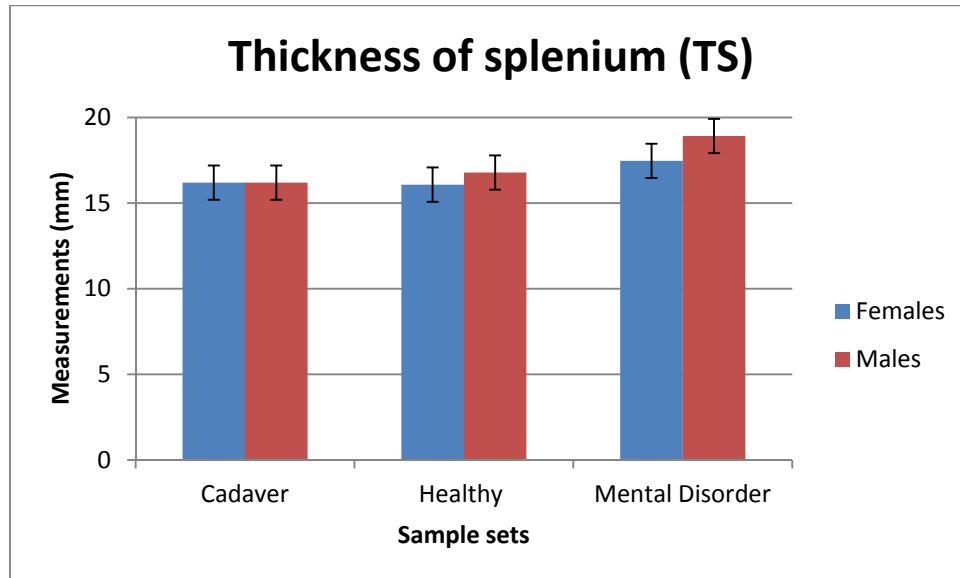
5.2.2 Thickness of the splenium (TS)

The splenium as defined by Witelson's partitioning method is the posterior one fifth of the CC, and thus measurements in this area will be referred to as the splenium (Witelson, 1989). The splenium is the area of the CC that has often been documented as demonstrating the most observed sexual dimorphism. It was first described in a study by De Lacoste and Holloway (1982) in which it was found that the splenium was larger in females than in males (De Lacoste and Holloway, 1982). The splenium in females was described as being more bulbous than that of males. This has been attributed to the fact that females are seen to perform better in language and somatosensory cognitive functioning (Broadfield *et al.*, 2001).

There was no statistically significant difference observed between the sexes in the cadaver sample ($p=0.72$), and in the healthy MRI scan sample ($p=0.09$). This is in agreement with a study conducted by Sungathy *et al.*, (2003), Westerhausen *et al.*, (2011) and Prendergrast *et al.*, (2015), where the authors found no substantial sexual dimorphism in the splenium ($p<0.05$). There was no statistically significant difference observed between the sexes in the mental disorder sample ($p=0.12$). This is in agreement with Collison *et al.*, (2014) in which it was observed that there was no statistically significance difference in the size of the splenium (Collison *et al.*, 2014). These were in contrast to a study conducted by Ellison-Wright *et al.*, (2014) in which it was observed that there was a statistically significant reduction in the size of

the splenium in schizophrenic patients ($p < 0.05$). The mean values of the thickness of the splenium is shown in Table 45 below.

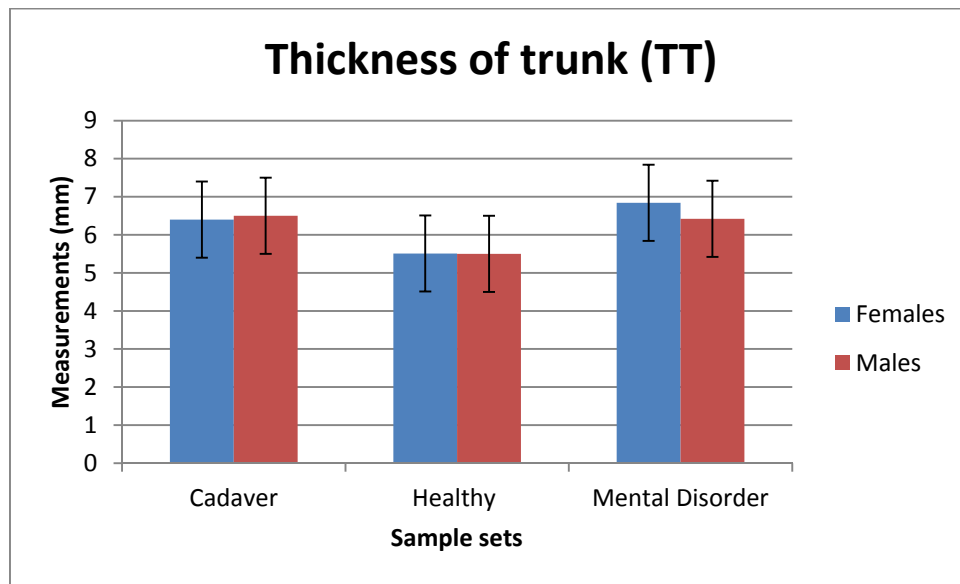
Table 45. Table showing thickness of splenium (TS)



5.2.3 Thickness of the trunk (TT)

According to Witelson's partitioning method, the corpus or trunk is the part of the CC that connects the genu anteriorly with the splenium posteriorly. This area can be further subdivided into the anterior midbody and the posterior midbody (Witelson, 1989). In this study, the midpoint of the CC was determined and the thickness of the trunk or corpus (TT) was measured at that point. There was no statistically significant difference observed between the sexes in the cadaver sample ($p = 0.88$) as well as the healthy MRI scan sample ($p = 0.95$). These results are in agreement with a study conducted by Sungathy *et al.*, (2003) and Ozdemir *et al.*, (2007). in which no sexual dimorphism in corpus width was detected. There was no statistically significant difference observed between the sexes in the mental disorder sample ($p = 0.19$). The mean values are shown in Table 46 below.

Table 46. Table showing thickness of trunk (TT)



The isthmus falls into Witelson’s definition of the trunk. In this study, the presence or absence of the isthmus was recorded. In the cadaver sample, an isthmus was present in 18 cases, 9 in the female sample and 9 in the male sample. In the healthy MRI sample, an isthmus was present in 32 cases, 17 in the female sample and 15 in the male sample. In both groups, the isthmus was present in 25% of the overall sample. This is in agreement with Raybaud (2010) who reported a similar figure. In the mental disorder CT sample, an isthmus was present in 22 cases, 6 in the female and 16 in the male sample. This represents 34,9% of the overall population.

It has been demonstrated in the literature that the CC plays an essential role in learning and behaviour (Sungathy *et al.*, 2003). Variations have been observed in mental disorders, thus, knowledge of the size and shape of the CC in normal adults is important. The baseline information gathered from CC morphological studies is essential for interpreting data from brains with mental disorders. The results from this study demonstrated that there were no sexual dimorphic differences observed between the sexes for all CC subregions measured for the three sample sets. However, there was a difference between the mean measurements of the various CC subregions between the cadaver and healthy MRI scan sample with the mental disorder CT scan sample. This suggests that a reference data set can be used for both males and females in the South African population for normal development of

the CC. Thus, if an individual fall outside of this reference range, it may be an indication for a mental disorder.

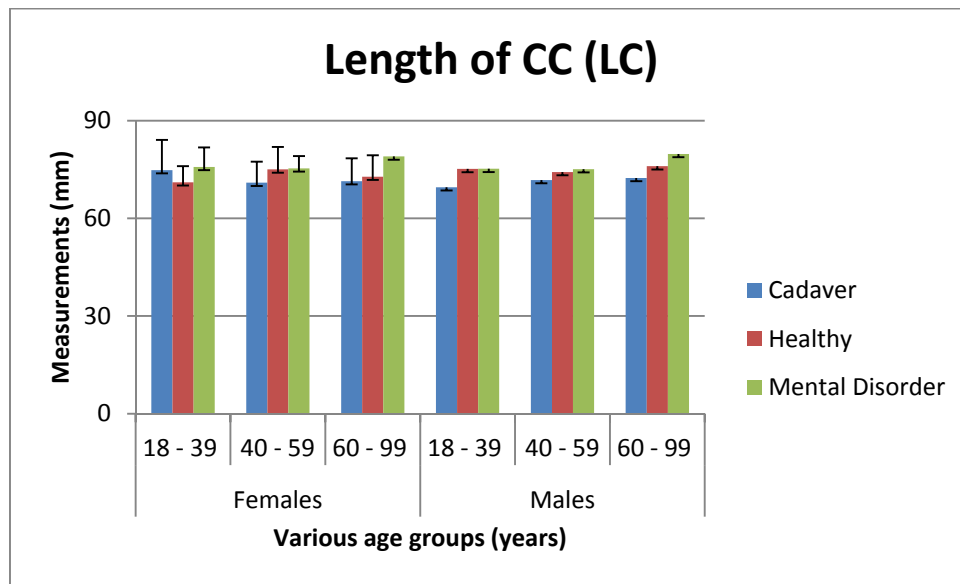
It is interesting to note that there were no sexual dimorphic differences in the various CC subregions between the mental disorders. This could be due to the small sample sizes and is an area that could benefit from future research.

5.3 Age differences in total midsagittal callosal length and length of the brain

5.3.1 *Length of the CC (LC)*

According to the straight line method used to partition the CC in this study, the length of the CC is described as the straight line that connects the most anterior point of the genu to the most posterior point of the splenium (Witelson, 1989). The individuals were divided into 18 – 39, 40 – 59 and 60 – 99 age groups for all parameters. In the cadaver sample, there was no statistically significant difference seen between the age groups ($p=0.85$). No statistically significant differences were observed for the length of the CC between the various age groups of the healthy MRI scan ($p=0.17$) sample. These results are consistent with a study by Sullivan *et al.*, (2001) in which there was no observable difference in the length of the CC as an individual aged ($p<0.05$) (Sullivan *et al.*, 2001). These results are in contrast to a study conducted by Sungathy *et al.*, (2003) where it was found that there was a statistically significant difference in the length of the CC in individuals over 40 years of age ($p=0.04$). In this study, no statistically significant differences were observed for the length of the CC between the various age groups of the mental disorder CT scan ($p=0.61$) sample. These results are smaller than what was observed in a meta-analysis by Woodruff *et al.*, (1995). The mean values are shown in Table 47 below.

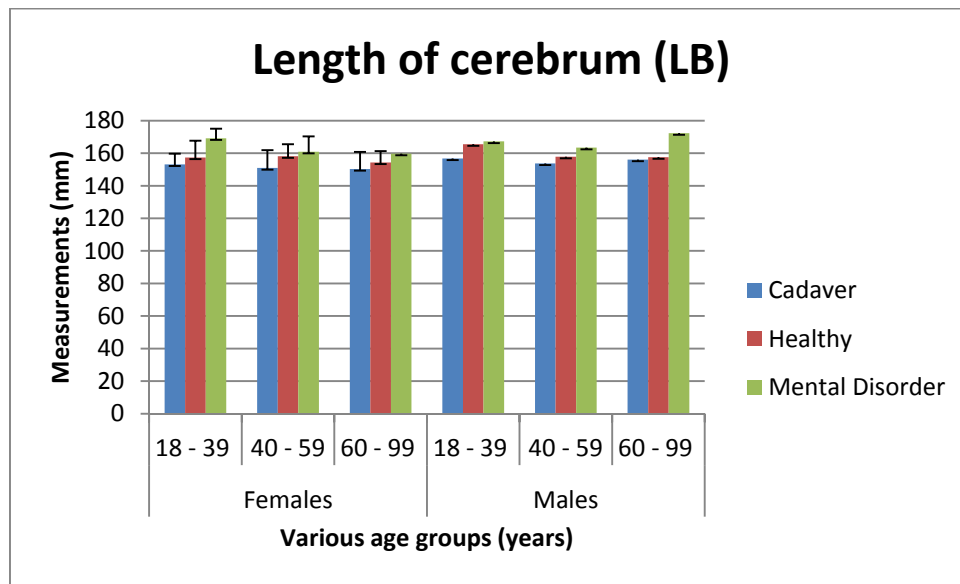
Table 47. Table showing length of CC (LC)



5.3.2 Length of the cerebrum (LB)

The length of the cerebrum (LB) was measured from the most anterior point of the cerebrum to the most posterior point of the cerebrum. There was no statistically significant difference seen between the age groups in the cadaver sample ($p=0.56$). In this study, no statistically significant differences were observed for the length of the cerebrum (LB) between the various age groups for the healthy MRI scan ($p=0.65$) samples. In this study, no statistically significant differences were observed for the length of the cerebrum (LB) between the various age groups for the mental disorder CT scan ($p=0.13$) samples. The mean values are shown in Table 48 below.

Table 48. Table showing length of cerebrum (LB)

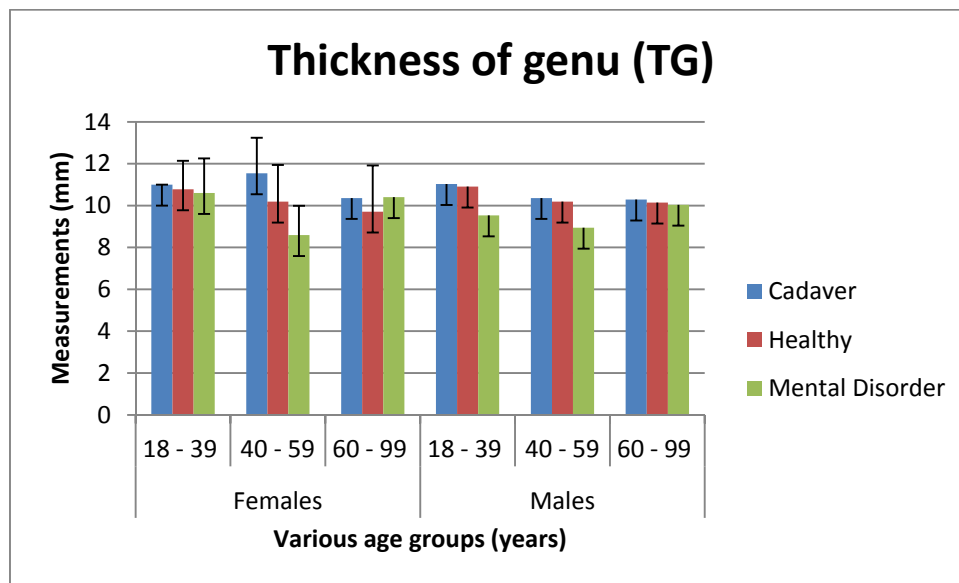


5.3.3. Thickness of the genu (TG)

The genu is an area that commonly demonstrates variation as an individual age (Dubb *et al.*, 2003). There was no statistically significant difference observed between the age groups in the cadaver sample ($p=0.30$) and healthy MRI sample ($p=0.08$). Sullivan *et al.*, (2001) found that the CC remains stable and that there are no variations with regard to the size and shape of the genu with regards to age (Sullivan *et al.*, 2001). This is in agreement with a study by Sungathy *et al.*, (2003) who also observed no differences ($p=0.99$). These results are in contrast with a study conducted by Prendergrast *et al.*, (2015) where it was found that the thickness of the genu decreased with age, with men having a sharper decline after approximately 30 years of life ($p<0.05$). (Prendergrast *et al.*, 2015) However, the study included individuals below the age of 18 years which may have influenced the results. In this study, there was no statistically significant difference observed between the various age groups in the mental disorder sample ($p=0.23$). The mean values are shown in Table 49 below.

It has been suggested that there is a loss of white matter with advancing age (Sungathy *et al.*, 2003). This apparent loss of white matter is suspected to influence the cognitive decline in elderly individuals. However, the results observed in this our study show that the thickness of the genu remains relatively stable throughout adult life.

Table 49. Table showing thickness of genu (TG)



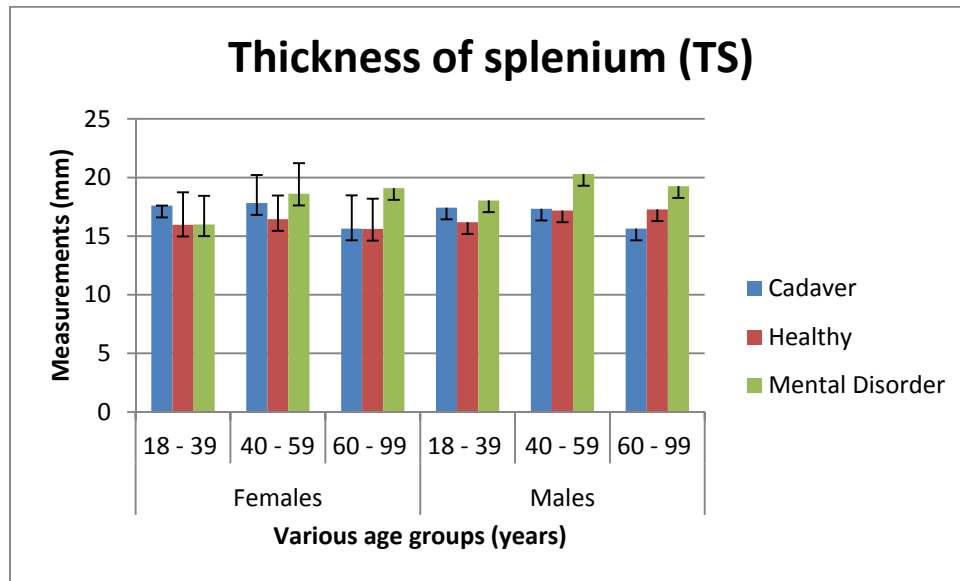
5.3.4 Thickness of the splenium (TS)

The splenium is an area of the CC that has been described in the literature to show deterioration with advancing age. In the cadaver sample there was a statistically significant difference observed between the various age groups for the thickness of the splenium (TS) in the cadaver sample ($p=0.02$). A Scheffe's test was performed in order to determine in which age groups the difference was observed. It was found that the splenium decreased in thickness with age. No statistically significant difference was observed between the groups measured ($p>0.05$) for all age groups compared. However, the difference was almost significant after the 6th decade of life ($p=0.06$), This is in agreement with a study conducted by Ota *et al.*, (2006) in which it was observed that the splenium decreased in length most prominently after the 6th decade ($p<0.05$) (Ota *et al.*, 2006). However, in a study by Gupta *et al.*, (2008) it was found that older females had a larger splenium (Gupta *et al.*, 2008). In the age group 41 – 60 years, it was observed that the splenium was 14.30 ± 0.13 mm, while in the male sample it was 11.8 ± 0.14 mm.

There was no statistically significant difference observed in the healthy MRI scan sample between the various age groups with regards to thickness of the splenium ($p=0.31$). A possible reason for this is that the MRI scan sample consisted mostly of individuals under the age of 60 years due to the availability of the scans, thus, over

60 years was under represented in the MRI sample. In a study by Sungathy *et al.*, (2003) no statistically significant difference was observed in the thickness of the splenium with age. There was no statistically significant difference observed between the various age groups in the mental disorder sample ($p=0.13$). The mean values are shown in Table 50 below.

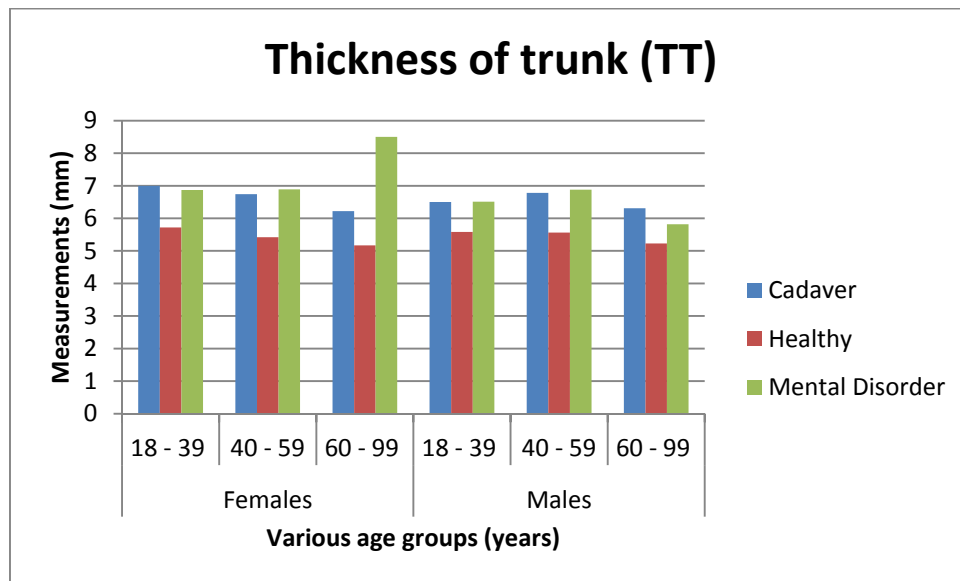
Table 50. Table showing thickness of splenium (TS)



5.3.5 Thickness of the trunk (TT)

There was no statistically significant difference seen between the age groups in the cadaver sample ($p=0.46$). There were no statistically significant differences in the thickness of the corpus or trunk (TT) between the various age groups healthy MRI scan sample ($p=0.17$). These results are in agreement with a study by Sungathy *et al.*, (2003) in which no statistically significant differences in the thickness of the corpus was observed. These results are in agreement with a study conducted by Ota *et al.*, (2006) in which it was seen that there were changes in the anterior midbody, but that there were no consistent changes on the thickness of the trunk as individuals aged. In the mental disorder there was no statistically significant difference observed between the various age groups ($p=0.58$). The mean values are shown in Table 51 below.

Table 51. Table showing thickness of trunk (TT)



It has been stated that loss of white matter is responsible for the cognitive decline seen in older individuals, and that the CC shrinks with age. As a result of this shrinkage with age, interhemispheric connectivity is compromised in the elderly population (Sungathy *et al.*, 2003). Any changes in CC morphology that can be considered as baseline information are important as any variations from what is deemed as normal development can be useful when studying pathological changes and the disease that result from it (Sungathy *et al.*, 2003).

In the present study, the results indicated that the various subregions of the CC remain stable over the adult life and there are no statistically significant differences, except for the thickness of the splenium (TS) in the healthy MRI scan sample. The latter was shown to decrease in thickness after the 4th decade of life. It is known that the splenium undergoes development well into adulthood and that the possible decline is due to the final end to that development (Giedd *et al.*, 1996). There were no age related changes observed in any of the other subregions measured. However, as the number of individuals in the various age groups was determined by the availability of the specimens or scans, this could have introduced a bias. For instance, in the cadaver group the mean age was 74 in females and in males it was 66 years of age. However, the mean age in the healthy MRI sample was 44 for females and 45 for males. Thus, there is a possibility that the unequal groups created a bias in the results. In the mental disorder sample, the mean age of females

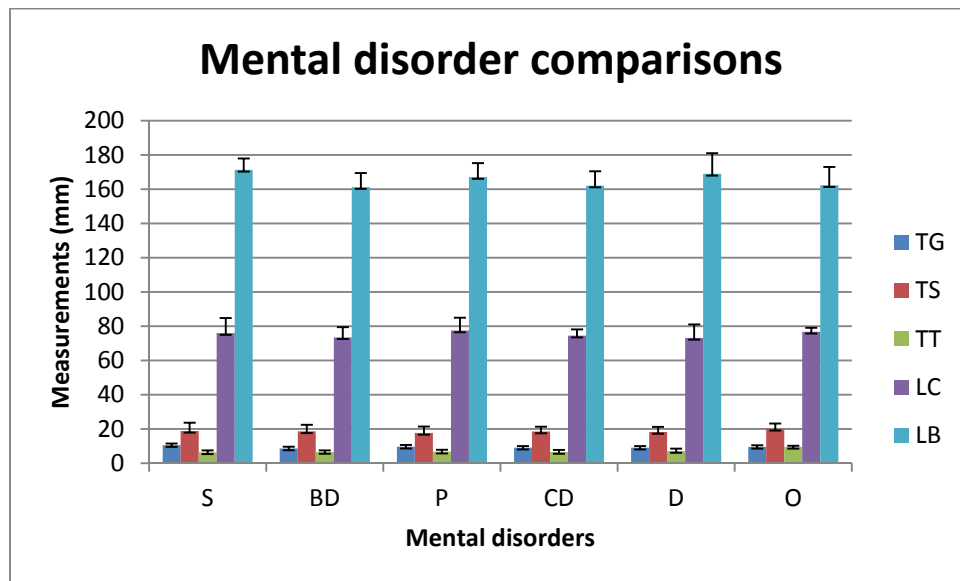
were 38 and in males it was 44 years of age. The majority of the sample was in the 18 – 29 and 30 – 39 age group. Thus, the older generations were not well represented. There is a possibility that any age related changes could not have accurately been observed as there was not a big enough sample to measure. An area for future research would be to follow individuals throughout their lifetime in order to make more accurate conclusions about the development of the CC. These results are in agreement with studies conducted by Sullivan *et al.*, (2001), Sungathy *et al.*, (2003) and Ota *et al.*, (2006), where no sexual dimorphism was observed in the samples.

5.4 Psychiatric differences in CC subregions

The mean of the various subregions (TT, TG, TT, LC and LB) of the CC were measured and compared between the mental disorders in order to determine if there was a statistically significant difference between the disorders. In this study schizophrenia (S), bipolar disorder (BD) and depression (D) mental disorders were compared. Patients who were suffering from cognitive deficits (CD) and psychosis (P) were also included, although these are not official diagnoses. There was also a group of disorders that was included as “other” (O).

There were no statistically significant differences observed between the mental disorders for the various parameters, $p > 0.05$ for all measurements. The mean values are shown in Table 52 below.

Table 52. Table showing comparisons between mental disorders



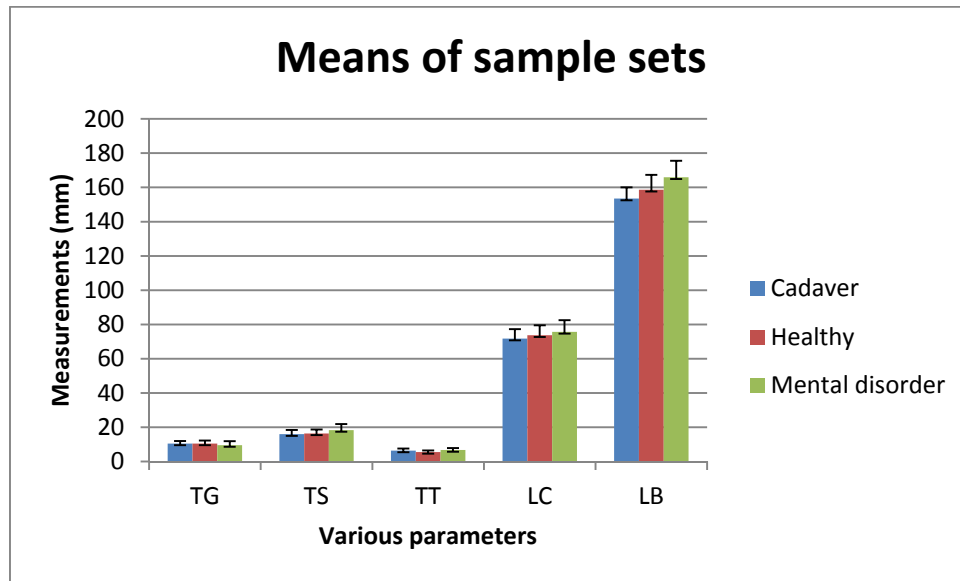
In this study it was observed that there were no statistically significant differences between the mental disorders. However, this could possibly be due to the fact that there were few representations of some of the mental disorders. Thus, the individuals in this study could not be an overall reflection of the population. This is a possible area for future research.

In this study, the mean thickness and linear lengths of the various subregions of the CC were measured. It has been observed that the majority of the literature makes use of volume and area comparisons between individuals suffering from mental disorders and healthy controls. This is therefore an area for future research where total area and volume of the sample should be measured and comparisons to the literature can then be made. Another aspect is that tensor diffusion is a new method of study that is used when researching functionality of mental disorders. This was not performed in this study and comparisons are hard to make. This is a potential for future research in comparing not only the anatomy but also the functional difference between psychiatric patients.

5.5 Comparison between the three sample sets

In this study, the three sample sets were compared in order to determine if there was a significant difference between the CC parameters measured. The mean values are shown in Table 53 below.

Table 53. Table showing comparisons between sample sets



The mean thickness of the genu was smaller in the mental disorder than in either the cadaver or healthy MRI scan sample. These results are in agreement with a study by Höppner *et al.*, (2001) where it was found that mental disorder patients had smaller genu than healthy controls ($p < 0.05$). It is also in agreement with a study by Ellison-Wright *et al.*, (2014) where it was found that schizophrenic patients had smaller genu than healthy controls ($p < 0.05$). Our study found no statistically significant difference between the cadaver and healthy MRI scan sample measurements. This suggests that reduction in callosal subregions not only has an effect on the overall cognitive functions of the individual, it also influences social skills and rapid problem solving that are seen in developmental mental disorders (Paul, 2011).

The mean thickness of the splenium was larger in the mental disorder sample than in either the cadaver or healthy MRI scan sample. These results are in contrast with a study by Ellison-Wright *et al.*, (2014) where it was found that schizophrenic patients had smaller splenium than healthy controls ($p < 0.05$). Li *et al.*, (2014) found that there

was a smaller splenium in schizophrenic and bipolar patients when compared to controls (Li *et al.*, 2014). This difference in results could be due to the resolution of the CT scans which could cause the author to over or under estimate the borders of the various subregions. The small sample size of the mental disorder patients could mean that there was not an accurate representation of mental disorder population, and that the individuals measured could be larger than normal. However, it has been shown that both the under and over development of the splenium has been linked to visuospatial impairments, attention deficits and reduction in motor coordination (Paul, 2011).

The healthy MRI scan sample had a reduced thickness of the trunk when compared to the cadaver and mental disorder CT scan sample. These results are in contrast with a study by Li *et al.*, (2014) in which a reduced width trunk was observed in schizophrenic and bipolar patients when compared to controls ($p < 0.05$). The results could be due to the different resolutions of the MRI and CT scans. The MRI scan sample was the largest out of all three and the mean age of the individuals was the lowest. This could introduce a bias as it has been stated that the CC undergoes development well into adulthood. Thus, the CC of the individuals measured was possibly not at the end stage of their development and thus were an underrepresentation.

The mean length of the CC was larger in the mental disorder CT scan sample than in the cadaver and healthy MRI scan sample. These results are supported by a study done by Höppner *et al.*, (2001) in which there was an overall reduced in length of the CC in mental disorder patients ($p < 0.05$). However, these results are contradicted by the results from a study by Colombo *et al.*, (1994), where it was found that the length of CC was reduced in patients and similar to the results reported by Collison *et al.*, (2014), where mental disorder patients had a reduction in the size of the CC. In a meta-analysis by Woodruff *et al.*, (1995) it was observed that the mean length of the CC of patients with schizophrenia was 69.0 ± 14.3 mm, while in the healthy controls it was 68.3 ± 15.1 mm. The results in their study was not statistically significant from one another.

The mental disorder sample had the largest mean length of the cerebrum when compared to the cadaver and healthy MRI scan samples.

These results demonstrated no statistically significant difference, except for two parameters, when comparing the information from the cadaver and healthy MRI scan sample. Thus, these results can be used interchangeably and a baseline reference data set can be compiled for the South African population using these results. It was observed that there was a statistically significant difference observed when comparing the mental disorder sample measurements with the cadaver and healthy MRI scan sample. Thus, there is a clear difference in normal CC morphology and those of individuals suffering from a mental disorder. These results can be used as a baseline for the possible indication and diagnosis of mental disorders in the South African population. Further research is needed in a larger sample in order to determine if there is a trend observed in the older healthy individuals compared to older individuals suffering from mental disorders.

The mean difference between the various age groups was also compared between the three sample sets. No statistically significant difference was observed between the sample sets with regard to the various age groups, all p-values were less greater than 0.05. However, there was a statistically significant difference observed in the thickness of the splenium (TS), it was found that the splenium decreased in size in the 60 – 99 age group. These results are consistent with a report by Ota *et al.*, (2006) in which it was seen that the splenium decreases in size after the 6th decade of life. This reduction in size when compared to younger age groups could be due to the fact that the splenium is known to continue development well into adulthood (Giedd *et al.*, 1996). Thus, the splenium would be considered “smaller” in older individuals once the development has stopped when compared with younger individuals who are still currently in the developmental process (Giedd *et al.*, 1996).

These results showed that there was a significant difference in some of the CC parameters as individuals age. These results could be due to the uneven distribution of the various age groups and that there were mental disorder individuals included in this comparison. As can be seen from the results above, the information between cadavers and healthy living samples can be used interchangeably. The same cannot

be said for the information gained from a mental disorder sample. Further research could be initiated to compare same size age groups between healthy and mental disorder samples to see the differences. The samples were combined together because of the uneven age groups, in some of the samples there was only one individual for an age group. Thus, to ensure an even sample size the three sample sets were combined in the age comparisons.

6 Conclusion

In this study there was no sexual dimorphism observed in the thickness of the genu, splenium and trunk in all three samples. In the cadaver sample there was also no difference in the length of the CC. In the mental disorder sample there was no sexual dimorphism in the length of the CC and cerebrum. However, in the cadaver sample there was a significant difference in the length of the cerebrum between the sexes. In the healthy MRI scan there was a statistically significant difference observed in the length of the CC and the length of the cerebrum.

It was found that there was no statistically significant difference in the thickness of the genu, trunk, and length of the CC and length of the cerebrum with age in all three samples measured. There was a statistically significant difference observed in the thickness of the splenium in the healthy MRI scan sample in individuals over the age of 60 years of age. This difference was not observed in the cadaver or mental disorder sample.

There were no statistically significant differences in the various CC parameters measured in the various mental disorders measured.

The overall samples were compared to one another in order to see if there was a significant difference. It was found, with the exception of two parameters, that there were no differences in measurements observed between the cadaver and healthy MRI sample. The two exceptions were the thickness of the trunk and the length of the cerebrum. This difference could be due to the quality of the preserved brains as the embalming technique is different among the Universities and this could introduce a difference. It could also be due to the fact that there was a rather large age difference between the cadaver and healthy MRI scan samples, thus, it could mean that these differences could be age related. This should be further investigated in a study where the cadaver and MRI scan samples are matched for age. Therefore, with the exception of the above mentioned cases, measurements between cadavers and living samples can be used interchangeably. Thus, the concerns about shrinkage in cadaver studies can be negligible.

However, when comparing the cadaver and healthy MRI scan sample with the mental disorder CT scan sample there was a statistically significant difference observed in every CC parameter measured. Thus, there is a rather noticeable difference in the anatomical structure of the CC in individuals suffering from mental disorders. Data on normal CC morphology is under represented in a South African population. Thus, observations of variations from normal CC morphology can be used as an indicator for the possibility of a diagnosis of a mental disorder.

6.1 Limitations

There were limitations to this study. The measurements made were on formalin-fixed cadavers and there is a possibility that the embalming technique could cause anatomical shrinkage or distortion that could alter the underlying anatomy (Schoeman, 2016, Acar *et al.*, 2017). However, studies have shown that these alterations are negligible and that the anatomy seen in a cadaveric sample is an accurate reflection of living samples (Schoeman, 2016). In the present study, with the exception of two parameters, it was seen that the differences between the measurements of the various CC parameters between the cadavers and healthy MRI scan sample were insignificant. Thereby proving that cadavers are an accurate representation of the living population and that the data gained from cadavers studies can be used interchangeably with those gained from living studies.

The cadaver sample size was determined by the availability of cadavers per University. At each University, a different formula for the embalming fluid was used and this could have impacted the quality of the brains and thus, introduced a bias in the sample. Also the general age of the cadaver sample was above 60 years of age. This meant that the comparisons between the age groups were uneven, and in some cases the age group had no representatives in the sample. This could have introduced a bias when it came to comparisons between the various age groups. The same limitation was observed in the MRI sample except that majority of the individuals were below 50 years of age, thus the older age groups were under represented and in some cases not represented at all. In the mental disorder CT scan sample there were few representations of individuals over the age of 40, thus this could have introduced a bias when comparisons between the three samples with

regard to age were conducted. The diagnoses of some of the mental disorders were not provided. As well as the fact that some of the mental disorders were under represented thus they are not accurately represented.

Another limitation was that there were no MRI scans available for the psychiatric patients. Only CT scans available, so those could be used to make the measurements for the psychiatric sample. There are different resolutions for CT and MRI scans and often the dimensions are underestimated as boundaries cannot always be clearly delineated because of either the resolution of the scan, the patient having moved or the presence of a soft tissue interface (Höhne and Hanson, 1992).

6.2 Future Research

The morphological reference data set will provide a quantitative data set for the diagnosis of certain neurological disorders in a South African population. The data set will aid in the diagnosis of neurological disorders, because – whenever the morphology of the CC goes out of the reference range provided – it will give an indication as to whether the individual is at risk of developing a mental disorder.

This study would benefit from future research into the overall shape differences of the CC and possibly a comparison of the total volumes between the sexes and ages. It would also be beneficial to increase the number of individuals in the various age groups in order to get a better representation of the overall sample. Another possible study would be to involve individuals who have relatively the same brain sizes in order to determine if there is sexual dimorphism in individuals of the same size and also introduce another sample group of fresh brains in order to compare the results gained from the cadaver samples as well as those from the imaging samples. Another branch of research would be to increase the number of individuals in each psychiatric group.

Much of the controversy in the literature is attributed to the different segmentation methods and how each defines the various subregions of the CC. Another potential

study would be to take the most commonly used methods of segmentation, and compare the results between them in order to determine whether a bias exists.

Future research using functional MRI could better compare the apparent differences between males and females when performing tasks that are generally performed better by one sex over the other. It could also give an indication as to how differently individuals who suffer from mental disorders perform those same tasks compared to healthy controls.

7 References

1. Acar, A. A., Bösenberg, A. T. and Schoor, A. N. 2017., Anatomical description of the sciatic nerve block at the subgluteal region in a neonatal cadaver population. *Pediatric Anesthesia*, 27, 643-647.
2. Allen, L.S., Richey, M.F., Chai, Y.M. and Gorski, R.A., 1991. Sex differences in the corpus callosum of the living human being. *The Journal of Neuroscience*, 11(4) 933-942.
3. Azer, S. A. and Eizenberg, N., 2007. Do we need dissection in an integrated problem-based learning medical course? Perceptions of first-and second-year students. *Surgical and Radiologic Anatomy*, 29, 173-180.
4. Bae, J. N., Macfall, J. R., Krishnan, K. R. R., Payne, M. E., Steffens, D. C. and Taylore, W. D., 2006. Dorsolateral prefrontal cortex and anterior cingulate cortex white matter alterations in late-life depression. *Biological psychiatry*, 60, 1356-1363.
5. Banich, M. T. and Belger, A., 1990. Interhemispheric interaction: how do the hemispheres divide and conquer a task? *Cortex*, 26, 77-94.
6. Bellani, M., Yeh, P.-H., Tansella, M., Balestrieri, M., Soares, J. C. and Brambilla, P., 2009. DTI studies of corpus callosum in bipolar disorder. Portland Press Limited.
7. Bernard, J. A. and Seidler, R. D., 2012. Hand dominance and age have interactive effects on motor cortical representations. *PloS one*, 7, e45443.
8. Bersani, G., Quartini, A., Paolemili, M., Clemente, R., Iannitelli, A., Di Biasi, C. and Gualdi, G. (2011). Neurological Soft Signs and Corpus Callosum morphology in schizophrenia. *Neuroscience Letters*, 499(3) 170-174.
9. Bishop, K. and Wahlsten, D. (1997). Sex Differences in the Human Corpus Callosum: Myth or Reality?. *Neuroscience & Biobehavioral Reviews*, 21(5) 581-601.
10. Bloom, J. and Hynd, G. (2005). The Role of the Corpus Callosum in Interhemispheric Transfer of Information: Excitation or Inhibition?. *Neuropsychol Rev*, 15(2) 59-71.
11. Bosman, MC, (2008). *Neuroanatomy 2nd edition*, UPrinters, Pretoria.
12. Brambilla, P., Nicoletti, M. A., Sassi, R. B., Mallinger, A. G., Frank, E., Kupfer, D. J., Keshavan, M. S. and Soares, J. C., 2003. Magnetic resonance imaging

- study of corpus callosum abnormalities in patients with bipolar disorder. *Biological psychiatry*, 54, 1294-1297.
13. Broadfield, D. C. 2001. Sex differences in the corpus callosum of *Macaca fascicularis* and *Pan troglodytes*.
 14. Chua, S., Sharma, T., Takeji, N., Murray, R. and Woodruff, P., 2000. A magnetic resonance imaging study of corpus callosum size in familial schizophrenic subjects, their relatives, and normal controls. *Schizophrenia research*, 41, 397-403.
 15. Clarke, E. and O'Malley, C. D., 1996. *The human brain and spinal cord: a historical study illustrated by writings from antiquity to the twentieth century*, Norman Publishing.
 16. Collinson, S. L., Gan, S. C., San Woon, P., Kuswanto, C., Sum, M. Y., Yang, G. L., Lui, J. M., Sitoh, Y. Y., Nowinski, W. L. and Sim, K. 2014., Corpus callosum morphology in first-episode and chronic schizophrenia: combined magnetic resonance and diffusion tensor imaging study of Chinese Singaporean patients. *The British Journal of Psychiatry*, 204, 55-60.
 17. Colombo, C., Bonfanti, A. and Scarone, S., 1994. Anatomical characteristics of the corpus callosum and clinical correlates in schizophrenia. *European archives of psychiatry and clinical neuroscience*, 243, 244-248.
 18. Constant, D. and Ruther, H. (1996). Sexual dimorphism in the human corpus callosum? A comparison of methodologies. *Brain Research*, 727(1-2) 99-106.
 19. Cook, N. D., 1984. Homotopic callosal inhibition. *Brain and language*, 23, 116-125.
 20. Duan, J.H., Wang, H.Q., Xu, J., Lin, X., Chen, S.Q., Kang, Z. and Yao, Z.B. 2006. White matter damage of patients with Alzheimer's disease correlated with the decreased cognitive function. *Surgical and Radiologic Anatomy*, 28, 150-156.
 21. Dubb, A., Gur, R., Avants, B. and Gee, J. (2003). Characterization of sexual dimorphism in the human corpus callosum. *NeuroImage*, 20(1) 512-519.
 22. Eberhardt, J. L. 2005., Imaging race. *American Psychologist*, 60, 181.
 23. Ellison-Wright, I., Nathan, P. J., Bullmore, E. T., Zaman, R., Dudas, R. B., Agius, M., Fernandez-Egea, E., Müller, U., Dodds, C. M. and Forde, N. J., 2014. Distribution of tract deficits in schizophrenia. *BMC psychiatry*, 14, 99.

24. Fenlon, L. and Richards, L. (2015). Contralateral targeting of the corpus callosum in normal and pathological brain function. *Trends in Neurosciences*, 38(5) 264-272.
25. Fiorentino, M., Monno, G. and Uva, A., Smart tools for virtual reality based cad. ADM-AIAS International Conference, 2004.
26. Finger, S., 2001. *Origins of neuroscience: a history of explorations into brain function*, Oxford University Press, USA.
27. Georgy, B., Hesselink, J. and Jernigan, T. (1993). MR imaging of the corpus callosum. *American Journal of Roentgenology*, 160(5) 949-955.
28. Giedd, J. N., Rumsey, J. M., Castellanos, F. X., Rajapakse, J. C., Kaysen, D., Vaituzis, A. C., Vauss, Y. C., Hamburger, S. D. and Rapoport, J. L., 1996. A quantitative MRI study of the corpus callosum in children and adolescents. *Developmental Brain Research*, 91, 274-280.
29. Glickstein, M. and Berlucchi, G., 2008. Classical disconnection studies of the corpus callosum. *Cortex*, 44, 914-927.
30. Gunderman, R. B. and Wilson, P. K., 2005. Exploring the human interior: The roles of cadaver dissection and radiologic imaging in teaching anatomy. *Academic Medicine*, 80, 745-749.
31. Gupta, T., Singh, B., Kapoor, K., Gupta, M. and Kochhar, S., 2008. Age and sex related variations in corpus callosal morphology. *Nepal Med. Coll. J*, 10(4) 215-21.
32. Holleran, L., Ahmed, M., Anderson-Schmidt, H., McFarland, J., Emsell, L., Leemans, A., Scanlon, C., Dockery, P., McCarthy, P., Barker, G.J. and McDonald, C., 2014. Altered interhemispheric and temporal lobe white matter microstructural organization in severe chronic schizophrenia. *Neuropsychopharmacology*, 39(4) 944-954.
33. Höhne, K. H. and Hanson, W. A., 1992. Interactive 3D segmentation of MRI and CT volumes using morphological operations. *Journal of computer assisted tomography*, 16, 285-294.
34. Höppner, J., Kunesch, E., Großmann, A., Tolzin, C. J., Schulz, M., Schläfke, D. and Ernst, K., 2001. Dysfunction of transcallosally mediated motor inhibition and callosal morphology in patients with schizophrenia. *Acta Psychiatrica Scandinavica*, 104, 227-235.
35. Just, M.A., Cherkassky, V.L., Keller, T.A., Kana, R.K. and Minshew, N.J.,

2007. Functional and anatomical cortical underconnectivity in autism: evidence from an fMRI study of an executive function task and corpus callosum morphometry. *Cerebral cortex*, 17(4) 951-961.
36. Kier, E. L. and Truwit, C. L., 1996. The normal and abnormal genu of the corpus callosum: an evolutionary, embryologic, anatomic, and MR analysis. *American Journal of Neuroradiology*, 17, 1631-1641.
37. Kwon, Y. H., Jang, S. H. and Yeo, S. S. 2014. Age-related changes of lateral ventricular width and periventricular white matter in the human brain: a diffusion tensor imaging study. *Neural regeneration research*, 9, 986.
38. Lebel, C., Caverhill-Godkewitsch, S. and Beaulieu, C. (2010). Age-related regional variations of the corpus callosum identified by diffusion tensor tractography. *NeuroImage*, 52(1) 20-31.
39. Li, J., Edmiston, E. K., Chen, K., Tang, Y., Ouyang, X., Jiang, Y., Fan, G., Ren, L., Liu, J. and Zhou, Y., 2014. A comparative diffusion tensor imaging study of corpus callosum subregion integrity in bipolar disorder and schizophrenia. *Psychiatry Research: Neuroimaging*, 221, 58-62.
40. Luders, E., Toga, A. and Thompson, P. (2014). Why size matters: Differences in brain volume account for apparent sex differences in callosal anatomy. *NeuroImage*, 84 820-824.
41. Lyoo, I. K., Kwon, J. S., Lee, S. J., Han, M. H., Chang, C. G., Seo, C. S., Lee, S. I. and Renshaw, P. F., 2002. Decrease in genu of the corpus callosum in medication-naive, early-onset *al.*, dysthymia and depressive personality disorder. *Biological psychiatry*, 52, 1134-1143.
42. Matsuo, K., Nielsen, N., Nicoletti, M. A., Hatch, J. P., Monkul, E. S., Watanabe, Y., Zunta-Soares, G. B., Nery, F. G. and Soares, J. C., 2010. Anterior genu corpus callosum and impulsivity in suicidal patients with bipolar disorder. *Neuroscience letters*, 469, 75-80.
43. Miles, K. 2005., Diagnostic imaging in undergraduate medical education: an expanding role. *Clinical radiology*, 60, 742-745.
44. Moran, P. M., Dharmatilleke, S., Khaw, A. H., Tan, K. W., Chan, M. L. and Rodriguez, I. 2006., Fluidic lenses with variable focal length. *Applied Physics Letters*, 88.
45. Mooshagian, E. (2008). Anatomy of the Corpus Callosum Reveals Its Function. *Journal of Neuroscience*, 28(7) 1535-1536.

46. Older, J., 2004. Anatomy: a must for teaching the next generation. *The Surgeon*, 2, 79-90.
47. Ota, M., Obata, T., Akine, Y., Ito, H., Ikehira, H., Asada, T. and Suhara, T. (2006). Age-related degeneration of corpus callosum measured with diffusion tensor imaging. *NeuroImage*, 31(4) 1445-1452.
48. Ozdemir, S. T., Ercan, I., Sevinc, O., Guney, I., Ocakoglu, G., Aslan, E. and Barut, C., 2007. Statistical shape analysis of differences in the shape of the corpus callosum between genders. *The anatomical record*, 290, 825-830.
49. Paul, L. K., 2010. Developmental malformation of the corpus callosum: a review of typical callosal development and examples of developmental disorders with callosal involvement. *Journal of neurodevelopmental disorders*, 3 (1), 3.
50. Pavlov, I. P. and Anrep, G. V. E., 1927. *Conditioned Reflexes. An Investigation of the Physiological Activity of the Cerebral Cortex... Translated and Edited by GV Anrep*, London.
51. Prendergast, D., Ardekani, B., Ikuta, T., John, M., Peters, B., DeRosse, P., Wellington, R., Malhotra, A. and Szeszko, P. (2015). Age and sex effects on corpus callosum morphology across the lifespan. *Human Brain Mapping*, 36(7) 2691-2702.
52. Raybaud, C., 2010. The corpus callosum, the other great forebrain commissures, and the septum pellucidum: anatomy, development, and malformation. *Neuroradiology*, 52(6) 447-477.
53. Reinoso-Barbero, F., Saavedra, B., Segura-Grau, E. and Llamas, A., 2014. Anatomical comparison of sciatic nerves between adults and newborns: clinical implications for ultrasound guided block. *Journal of anatomy*, 224, 108-112.
54. Ryberg, C., Stegmann, M.B., Sjöstrand, K., Rostrup, E., Barkhof, F., Fazekas, F. and Waldemar, G., 2006. Corpus callosum partitioning schemes and their effect on callosal morphometry. In *14th Scientific Meeting and Exhibition of International Society for Magnetic Resonance in Medicine*.
55. Salat, D., Ward, A., Kaye, J. and JanoTSky, J. (1997). Sex Differences in the Corpus Callosum With Aging. *Neurobiology of Aging*, 18(2) 191-197.
56. Schoeman, M., 2016. The creation of an arterial anatomy reference data set for a South African population.

57. Suganthy, J., Raghuram, L., Antonisamy, B., Vettivel, S., Madhavi, C. and Koshi, R. (2003). Gender- and age-related differences in the morphology of the corpus callosum. *Clin. Anat.*, 16(5) 396-403.
58. Sullivan, E., Rosenbloom, M., Desmond, J. and Pfefferbaum, A. (2001). Sex differences in corpus callosum size: relationship to age and intracranial size. *Neurobiology of Aging*, 22(4) 603-611.
59. Suri, A., Roy, T. S., Lalwani, S., Deo, R. C., Tripathi, M., Dhingra, R., Bhardwaj, D. N. and Sharma, B. S., 2014. Practical guidelines for setting up neurosurgery skills training cadaver laboratory in India. *Neurology India*, 62, 249.
60. Teipel, S. J., Bayer, W., Alexander, G. E., Zebuhr, Y., Teichberg, D., Kulic, L., Schapiro, M. B., Möller, H.J., Rapoport, S. I. and Hampel, H., 2002. Progression of corpus callosum atrophy in Alzheimer disease. *Archives of Neurology*, 59, 243-248.
61. Tuncer, M., Hatipoğlu, E. and Özateş, M. (2005). Sexual dimorphism and handedness in the human corpus callosum based on magnetic resonance imaging. *Surgical and Radiologic Anatomy*, 27(3) 254-259.
62. Wang, X.D., Ren, M., Zhu, M.W., Gao, W.P., Zhang, J., Shen, H., Lin, Z.G., Feng, H.L., Zhao, C.J. and Gao, K., 2015. Corpus callosum atrophy associated with the degree of cognitive decline in patients with Alzheimer's dementia or mild cognitive impairment: A meta-analysis of the region of interest structural imaging studies. *Journal of psychiatric research*, 63, 10-19.
63. Westerhausen, R., Kompus, K., Dramsdahl, M., Falkenberg, L., Grüner, R., Hjelmervik, H., Specht, K., Plessen, K. and Hugdahl, K. (2011). A critical re-examination of sexual dimorphism in the corpus callosum microstructure. *NeuroImage*, 56(3) 874-880.
64. Westerhausen, R., Kreuder, F., Woerner, W., Huster, R., Smit, C., Schweiger, E. and Wittling, W. (2006). Interhemispheric transfer time and structural properties of the corpus callosum. *Neuroscience Letters*, 409(2) 140-145.
65. Witelson, S.F., 1989. Hand and sex differences in the isthmus and genu of the human corpus callosum. *Brain*, 112(3) 799-835.
66. Woodruff, P., McManus, I. and David, A., 1995. Meta-analysis of corpus callosum size in schizophrenia. *Journal of Neurology, Neurosurgery & Psychiatry*, 58, 457-461.

67. Wu, J. C., Buchsbaum, M. S., Johnson, J. C., Hershey, T. G., Wagner, E. A., Tung, C. and Lottenberg, S., 1993. Magnetic resonance and positron emission tomography imaging of the corpus callosum: size, shape and metabolic rate in unipolar depression. *Journal of affective disorders*, 28, 15-25.
68. Young, R. R. 2006. Schmidek and Sweet's Operative Neurological Techniques: Indications, Methods, and Results. *The journal of spinal cord medicine*, 29, 240.